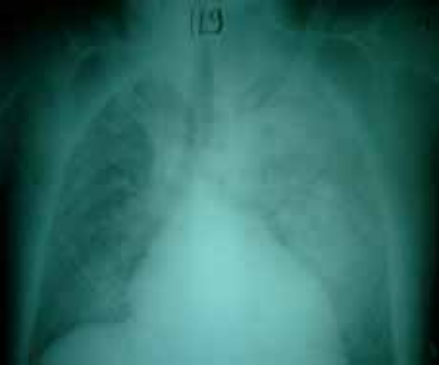



Radiographies pulmonaires critiques



André Denault FRCPC, CSPQ, ABIM-CCM
Professeur agrégé de clinique
Département d'anesthésiologie
Institut de Cardiologie de Montréal
Service des soins intensifs
Centre Hospitalier Universitaire de Montréal

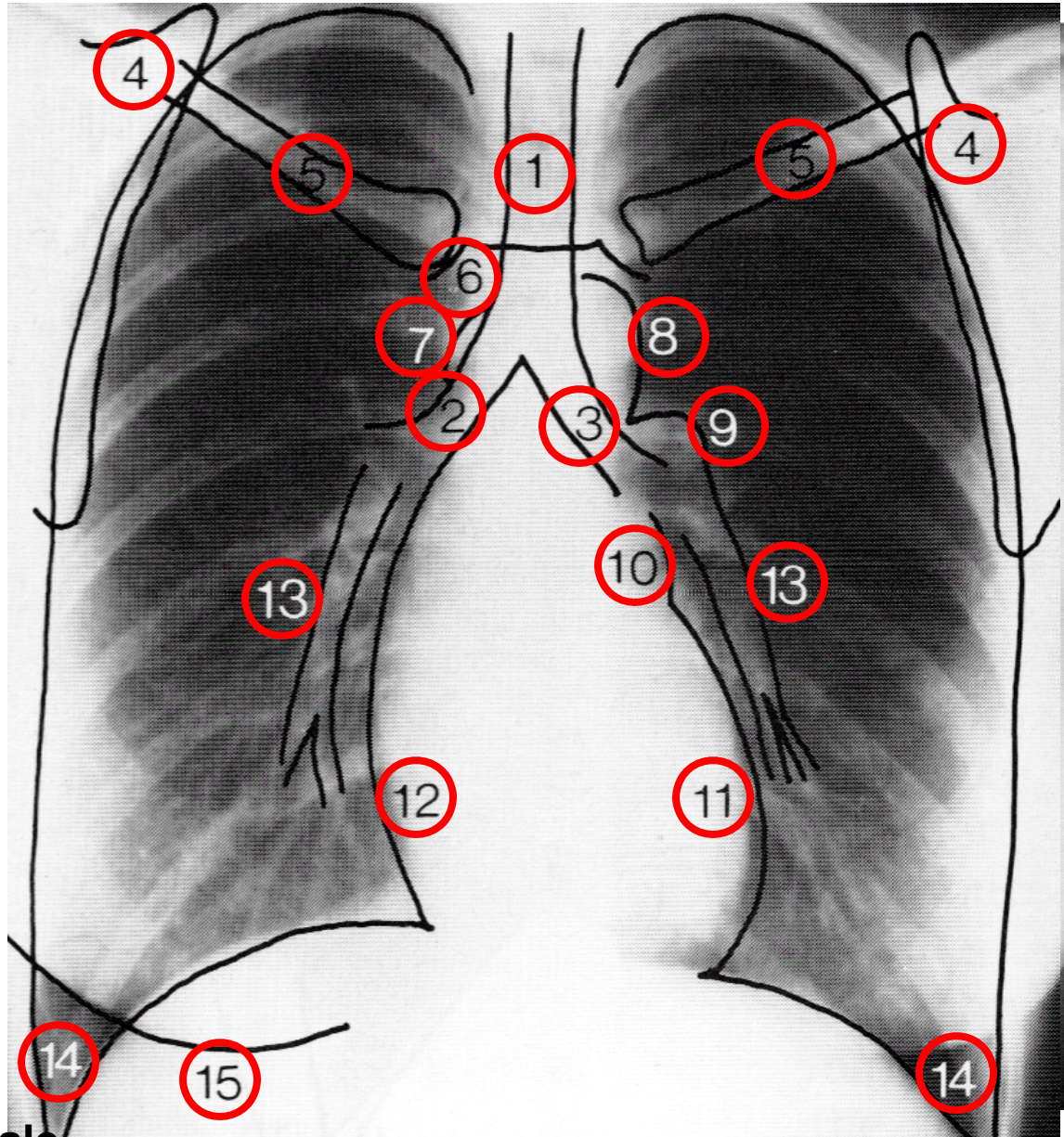
Montréal 2007

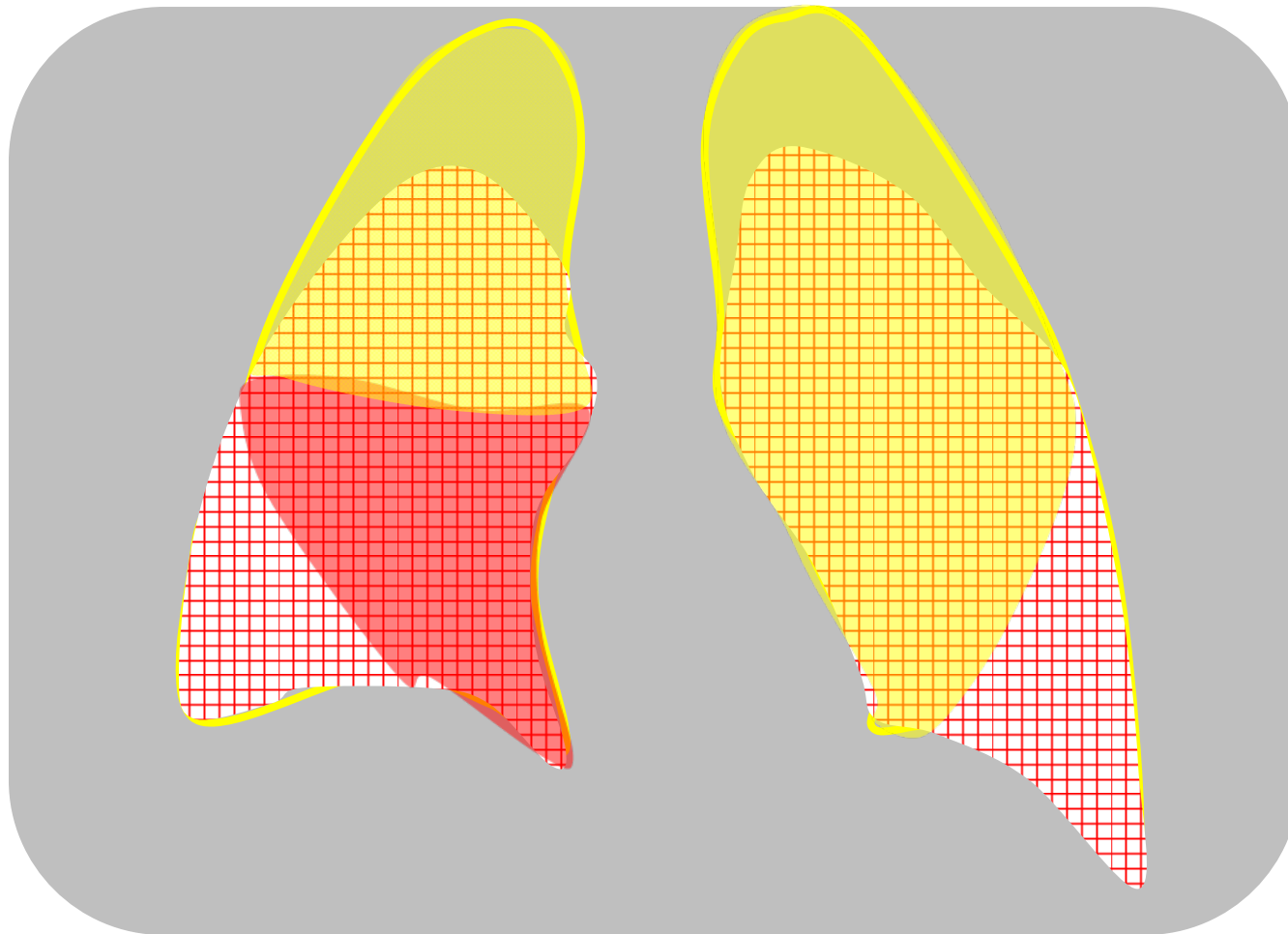


Université 
de Montréal



- 1 Trachée
- 2 Bronche souche dr
- 3 Bronche souche g
- 4 Omoplate
- 5 Clavicule
- 6 Sternum
- 7 Veine azygos
- 8 Crosse aortique
- 9 Artère pulm g
- 10 Bordure cardiaque sup g
- 11 Bordure cardiaque inf g
- 12 Oreillette droite
- 13 Artère du lobe inf
- 14 Angle costophrénique latérale
- 15 Sein






Lobe supérieur

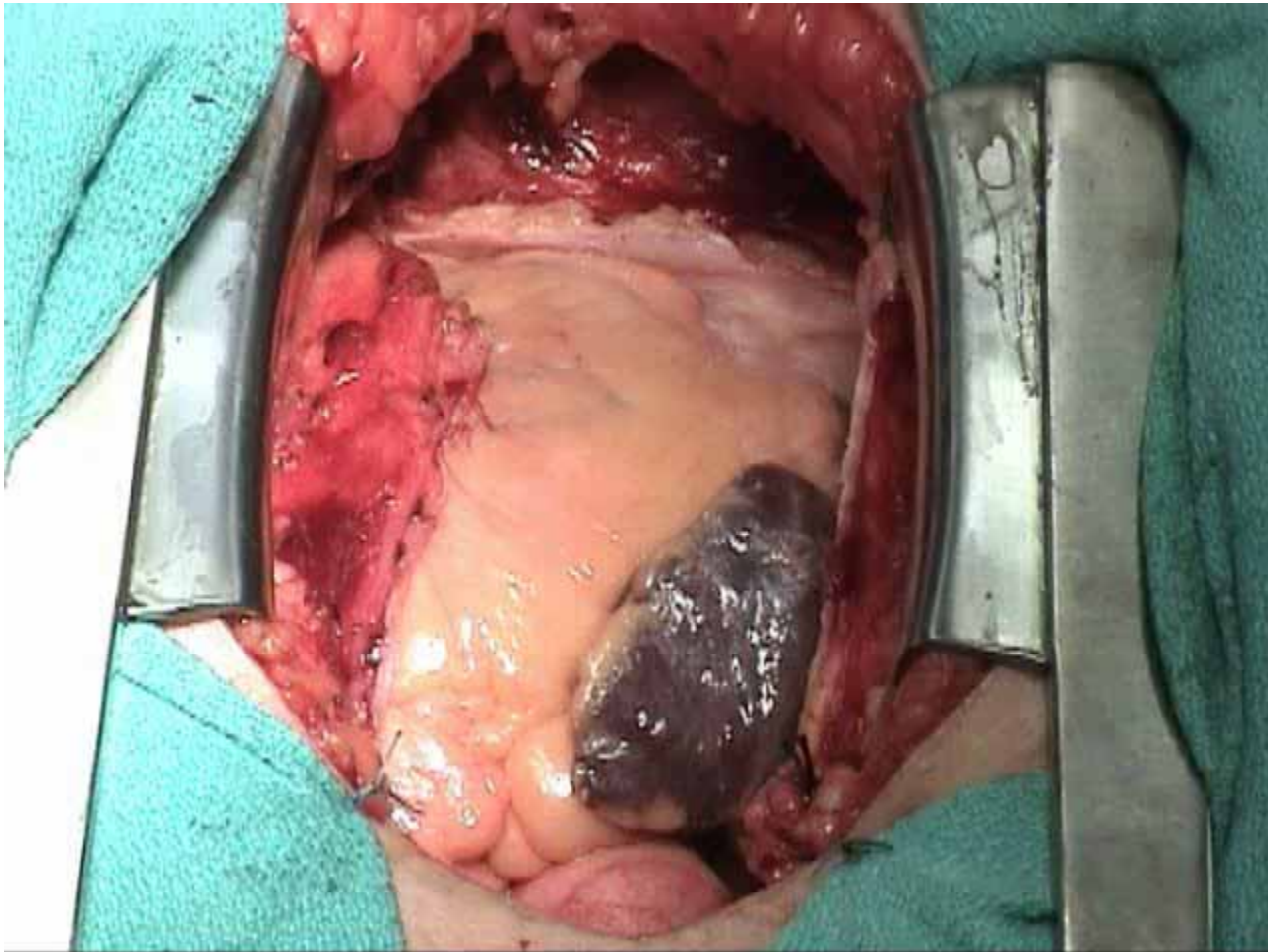


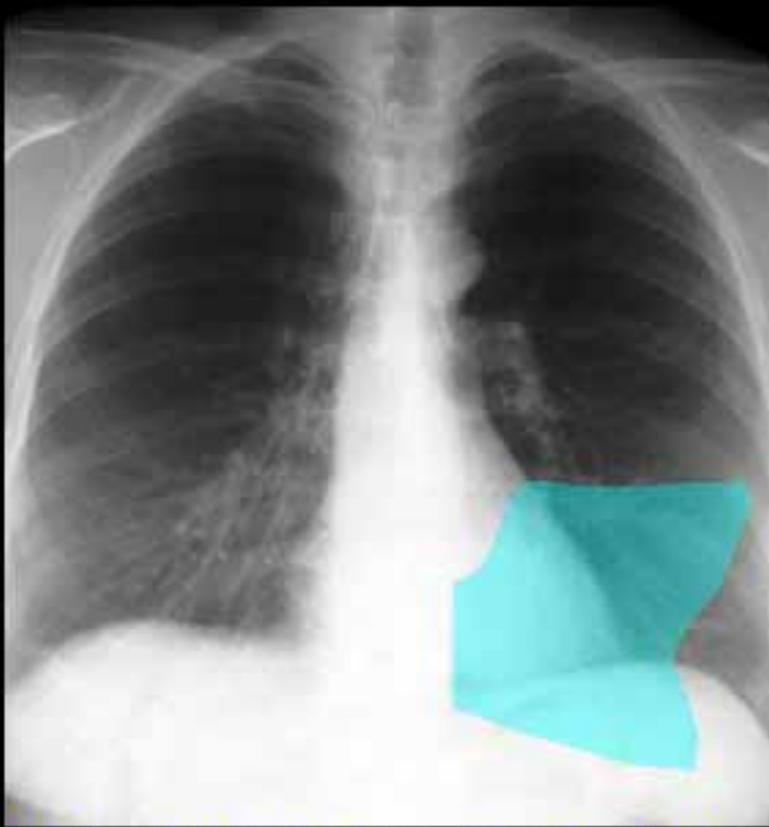
Lobe moyen



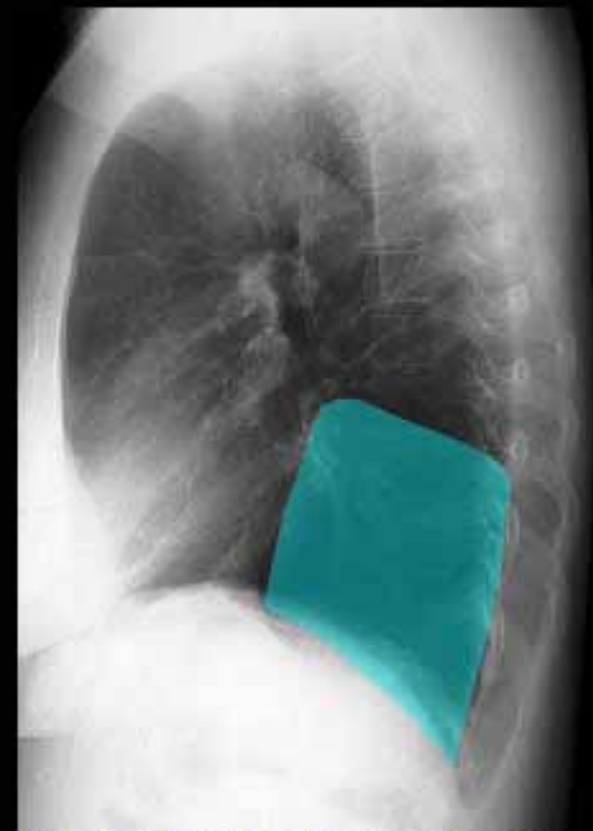
Lobe inférieur

Aspect intraopératoire

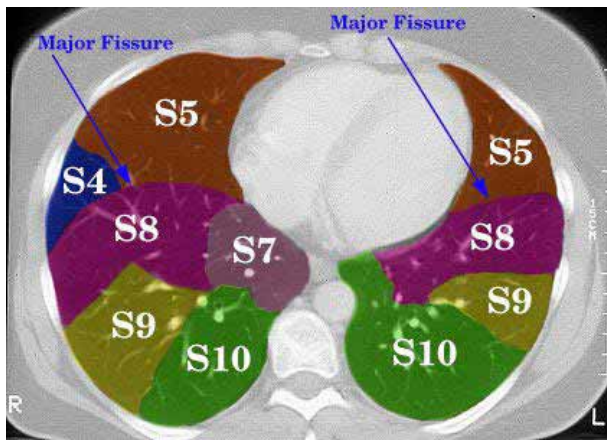




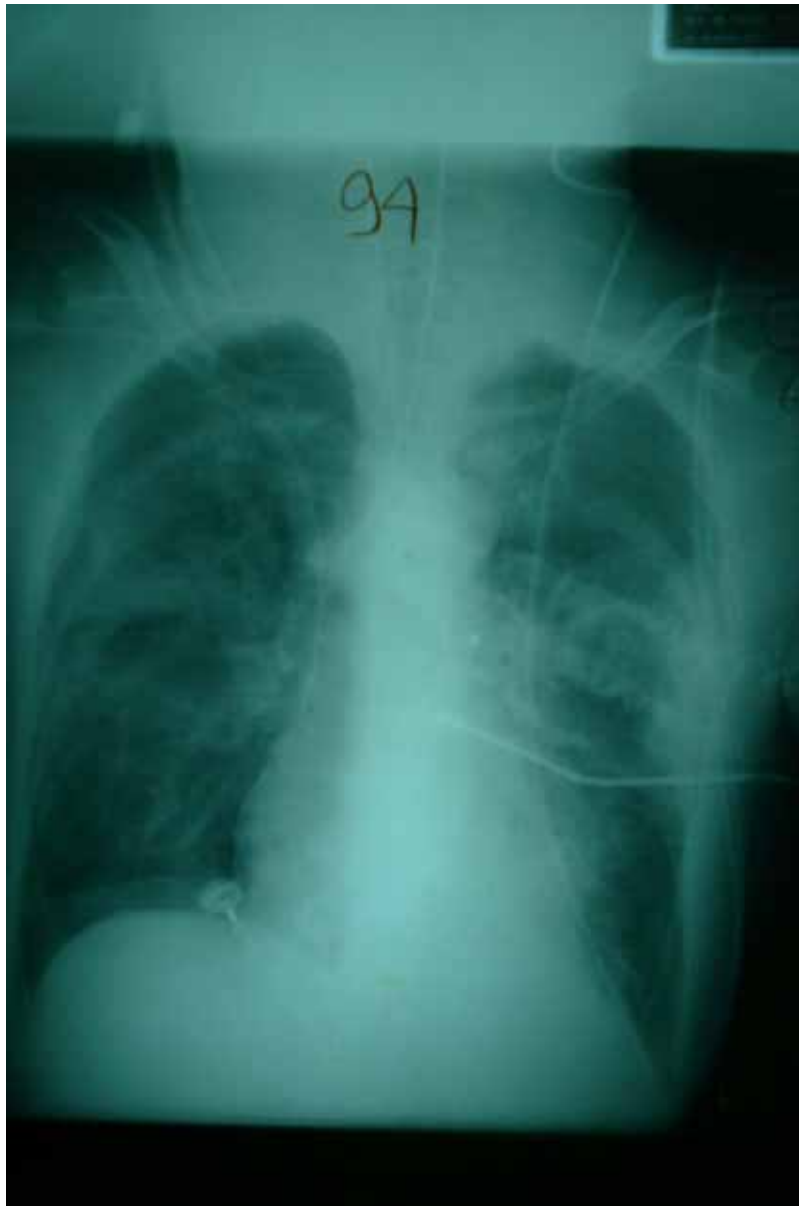Posterior basilar segment of the left lower lobe (S10).



Posterior basilar segment of the left lower lobe (S10).



Virtual Hospital 2002

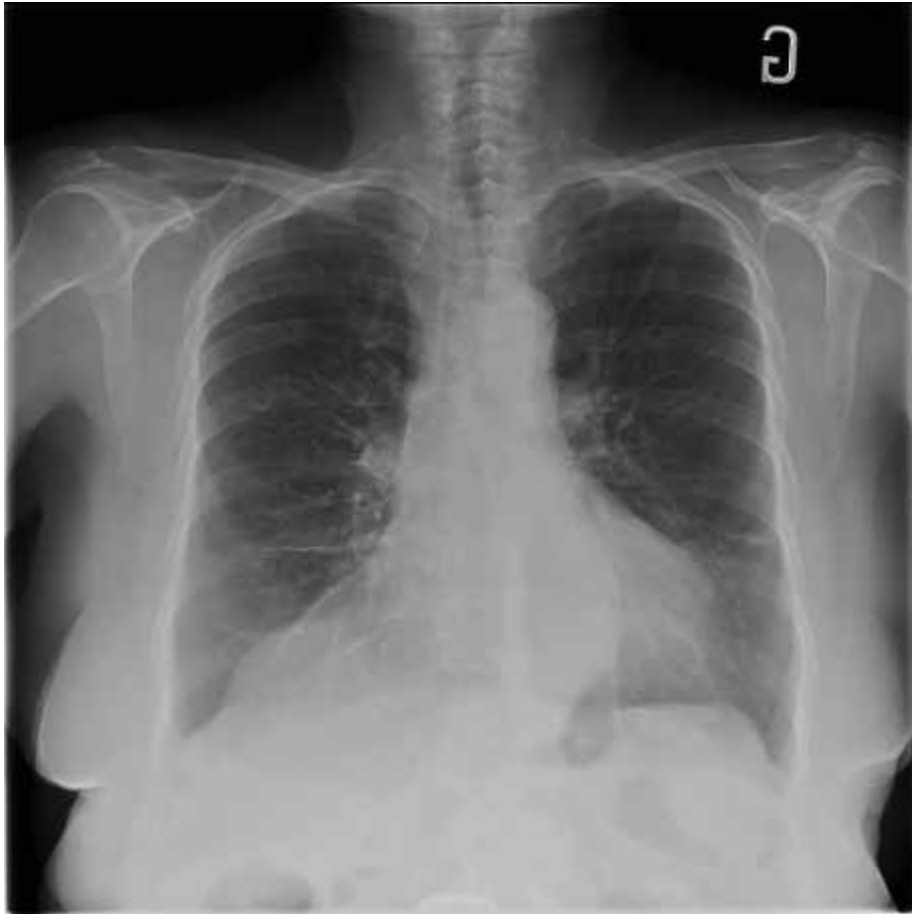


Infiltrats:

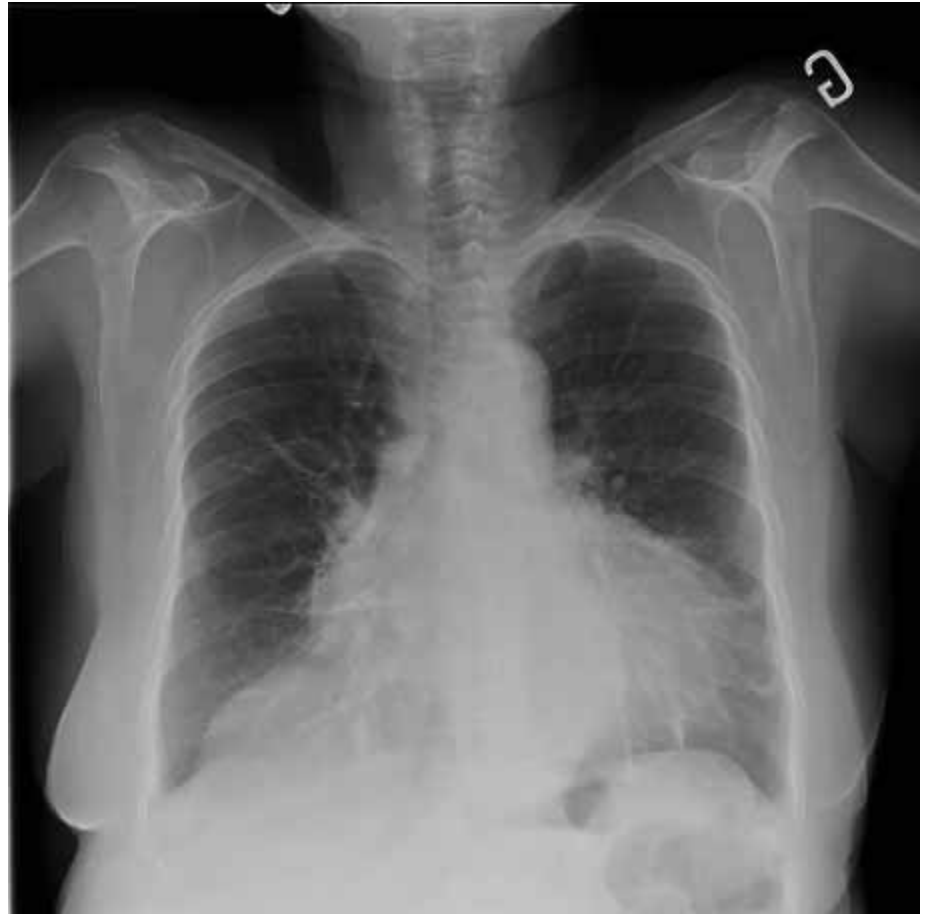- eau
- sang
- pus
- gavage

Radiographie de routine post-op de HSA V jour 6

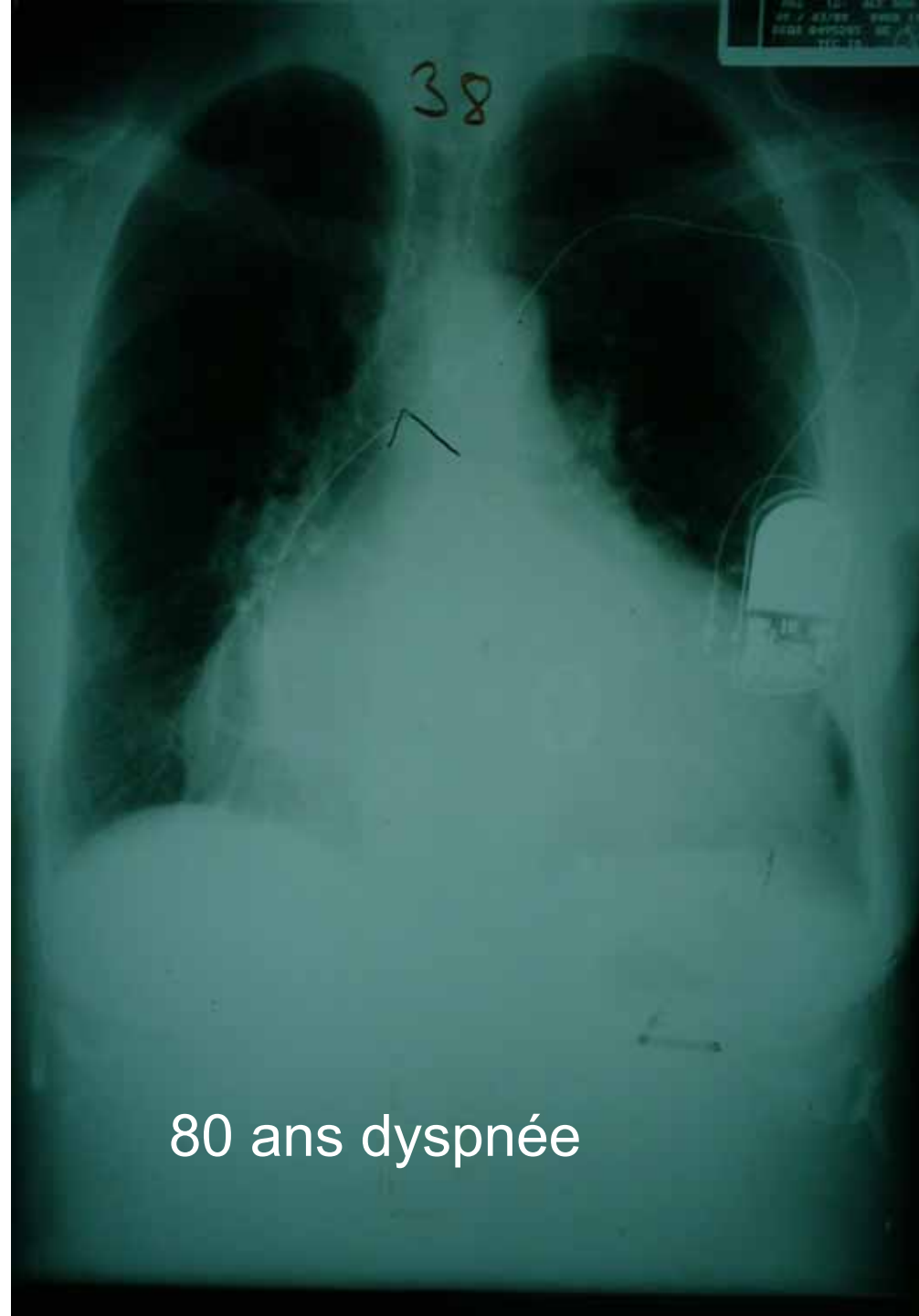
Patiente de 75 ans dyspnéique



Aout 2007



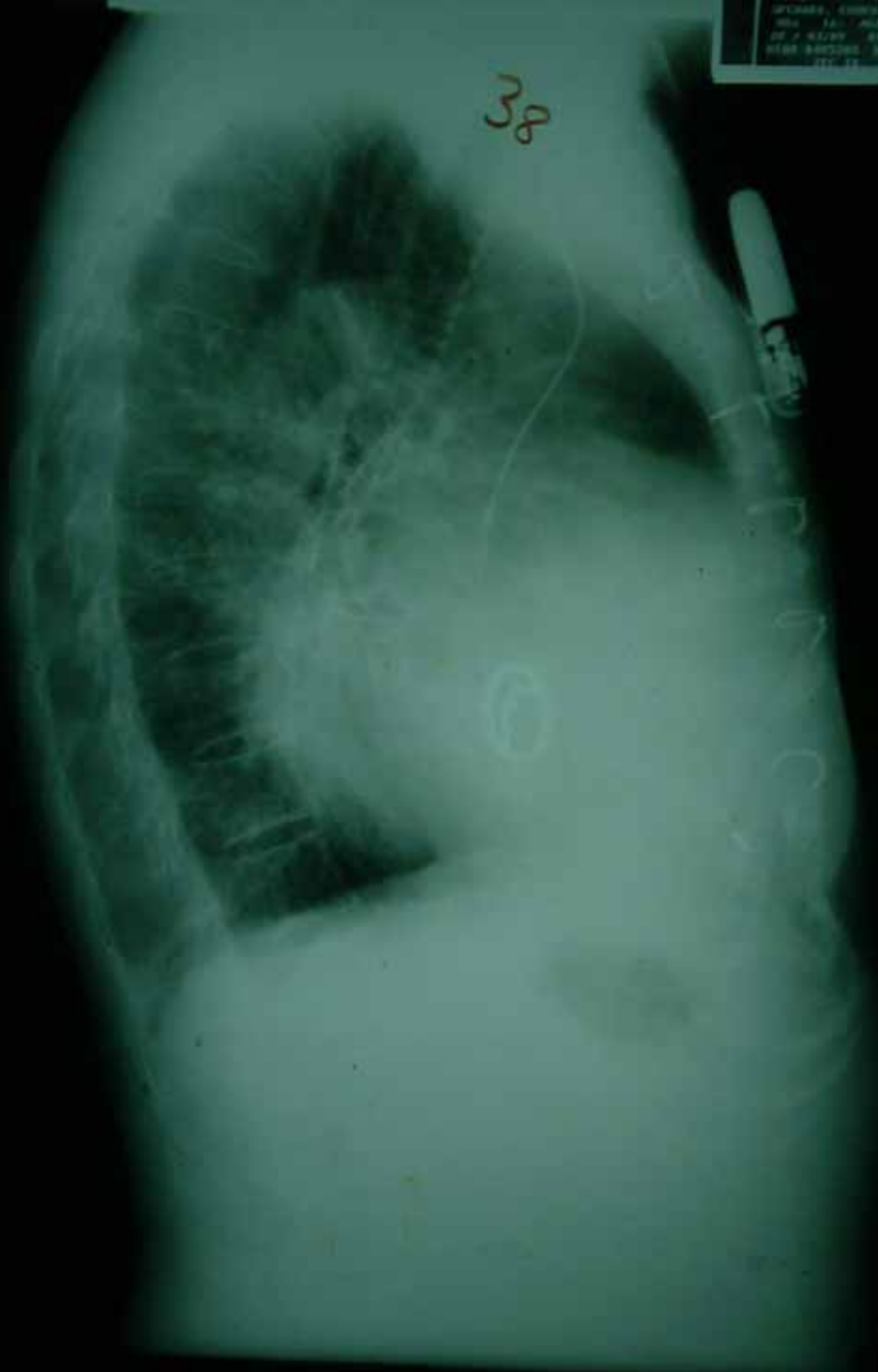Septembre 2007



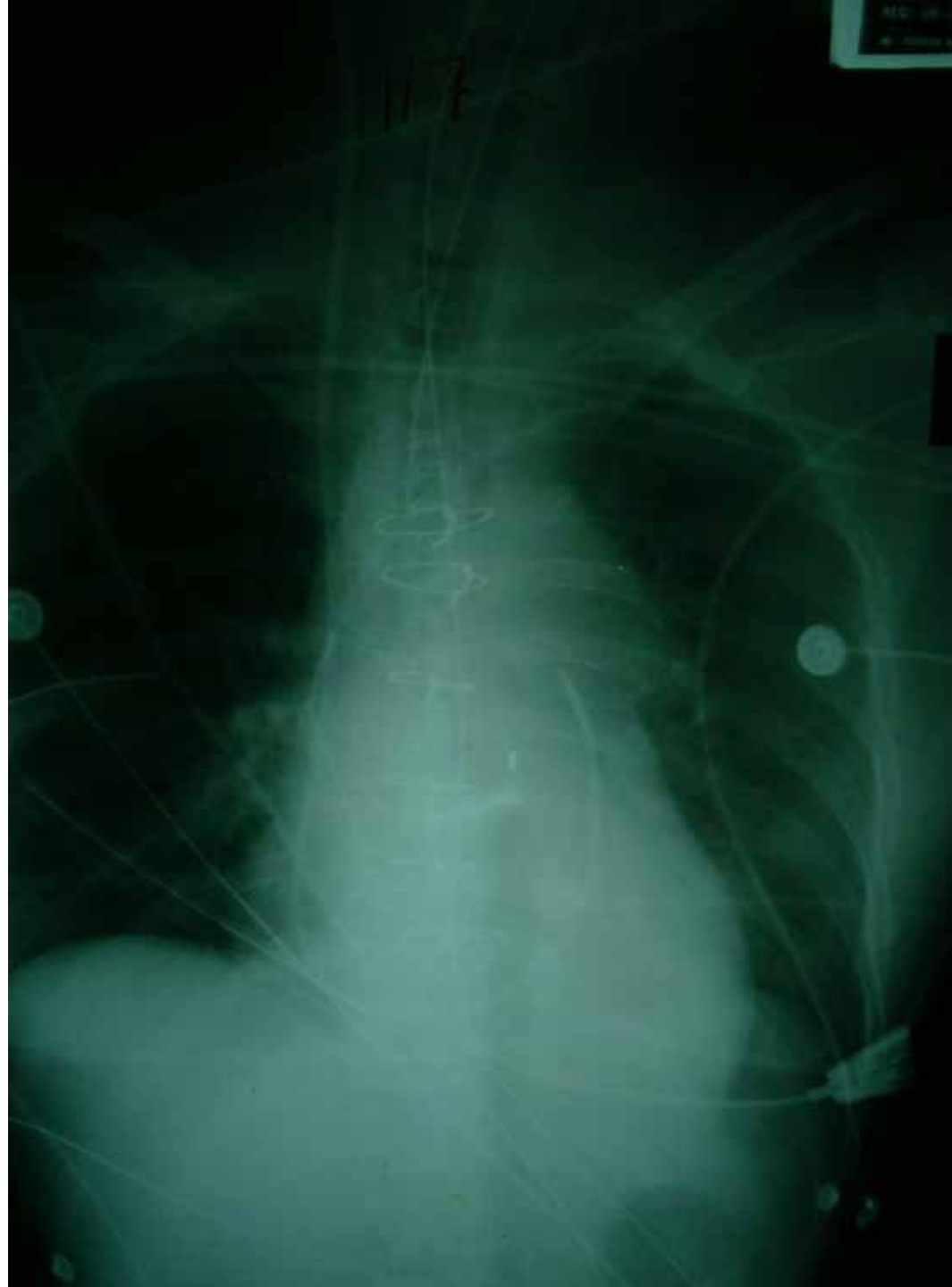
80 ans dyspnée

ARCADIA, CALIFORNIA
MAY 14, 1962
DR. J. H. W. 8000
STATE 8482200, 80
117, 11

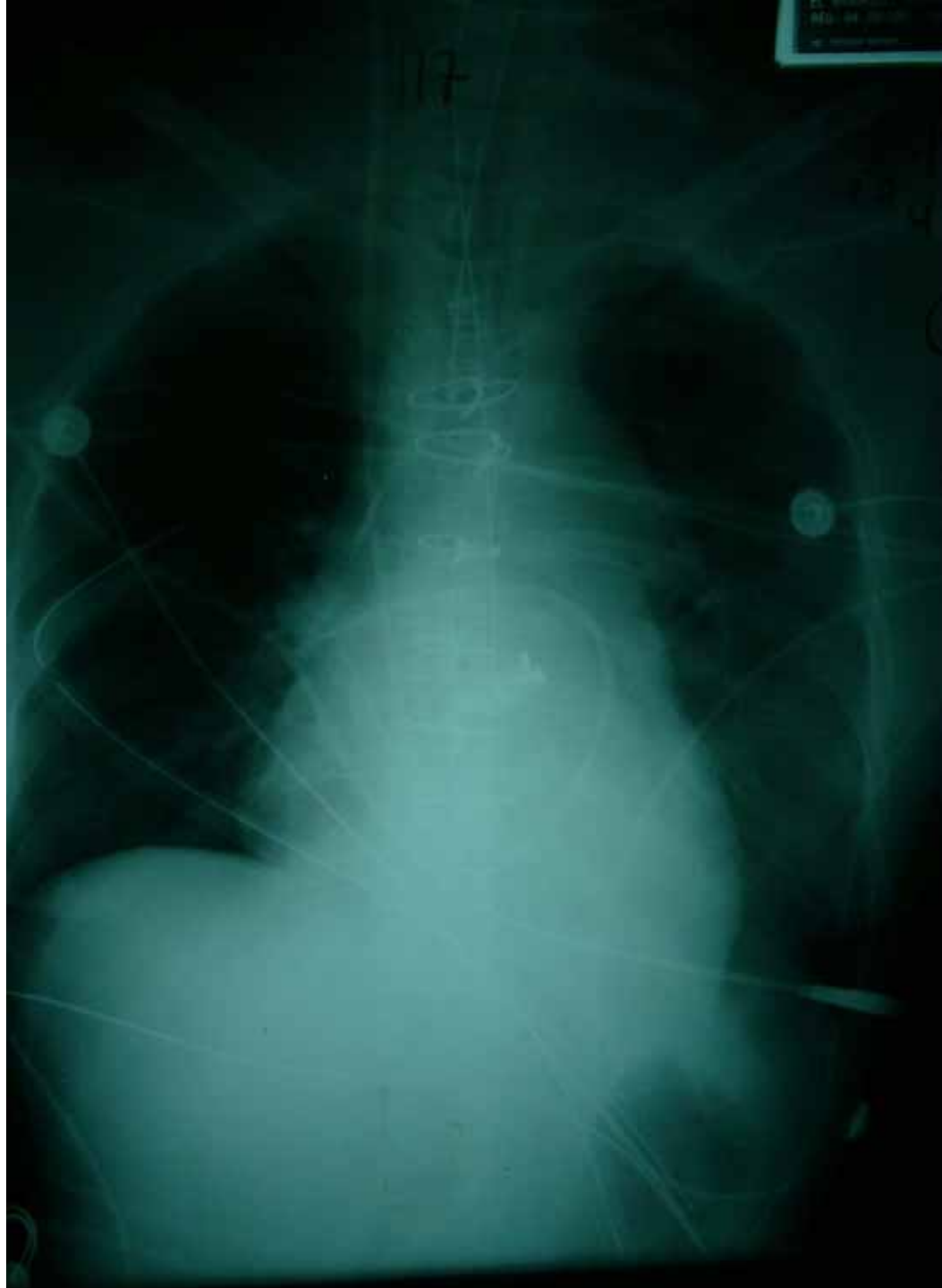
38

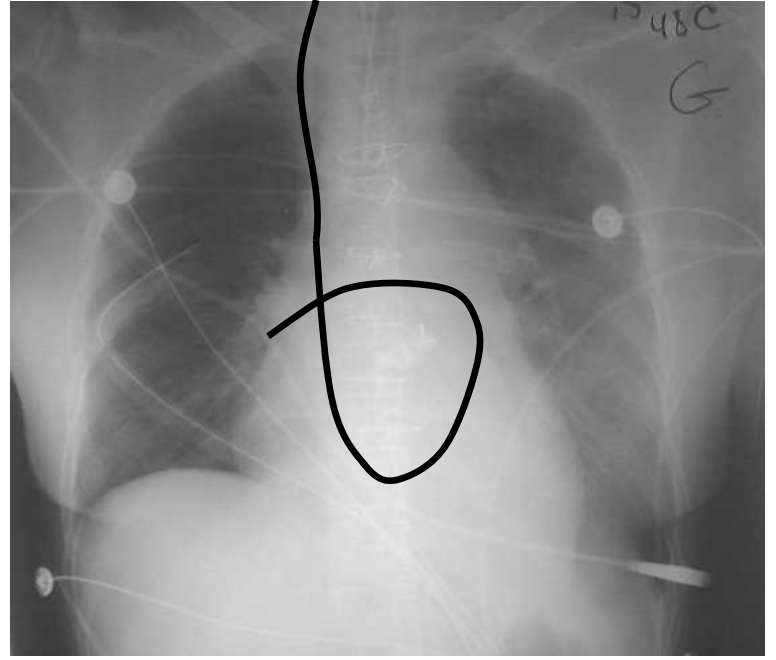
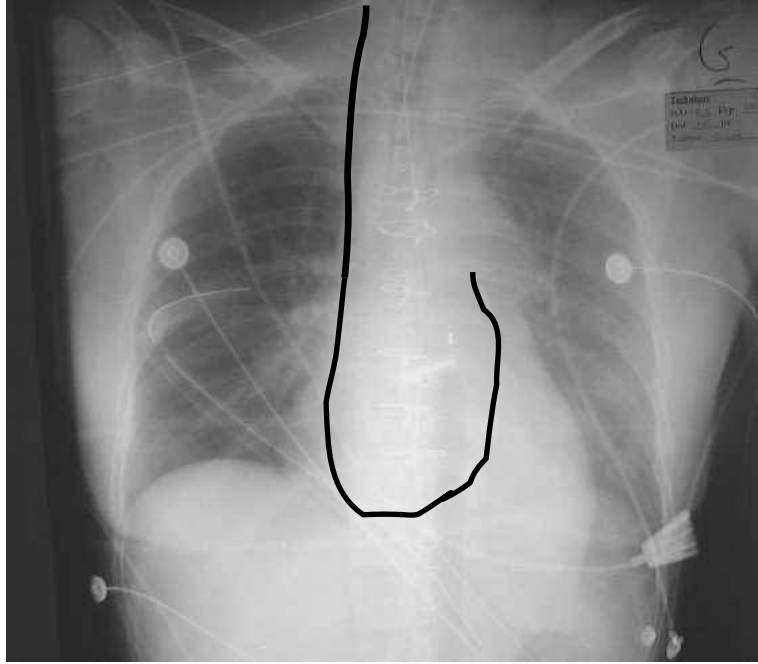


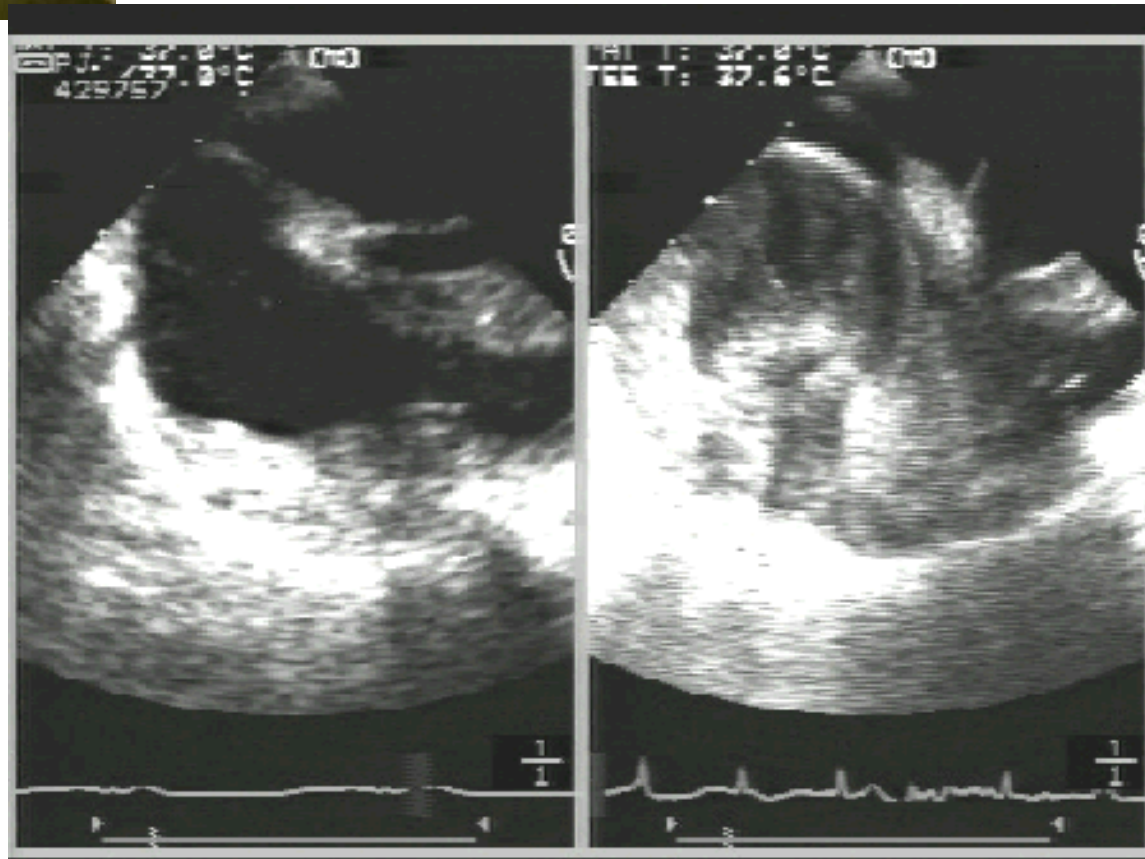
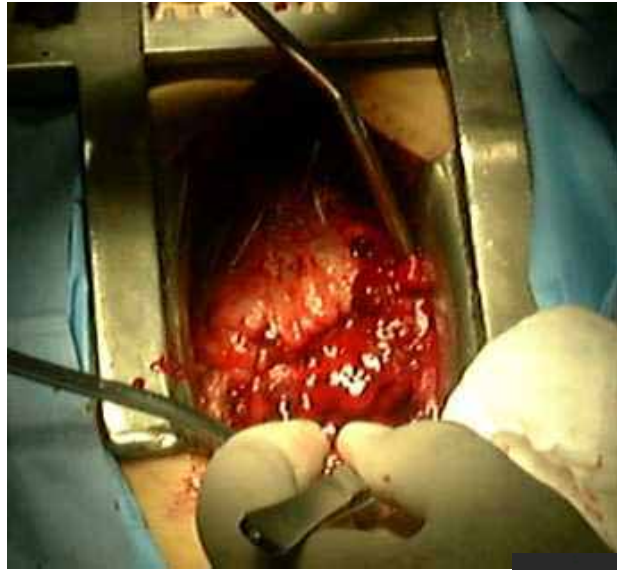
♀ 34 ans post-
chirurgie aortique
(Cabrol jour #1)



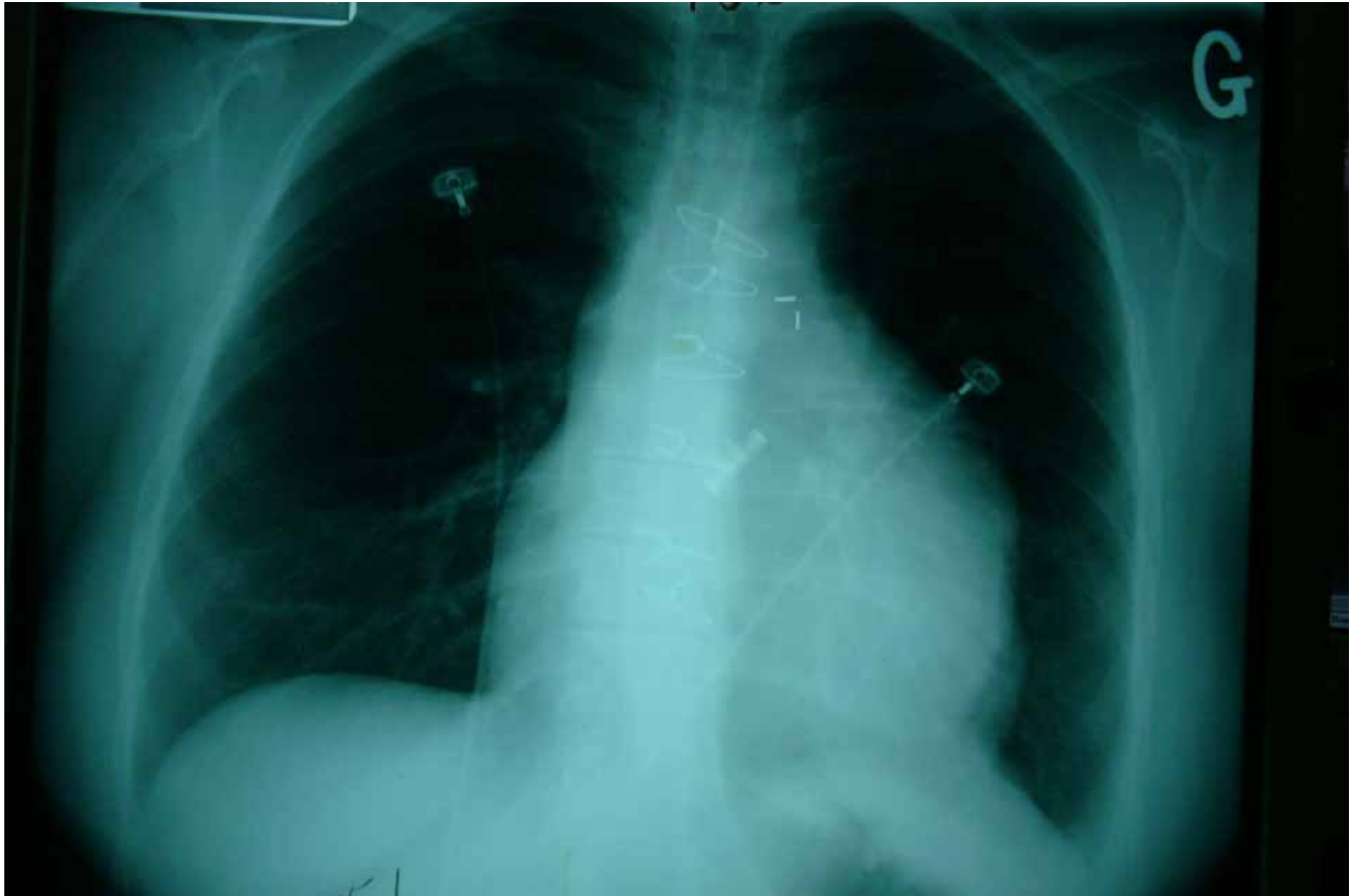
♀ 34 ans post-
chirurgie aortique
(Cabrol jour #2):
instable

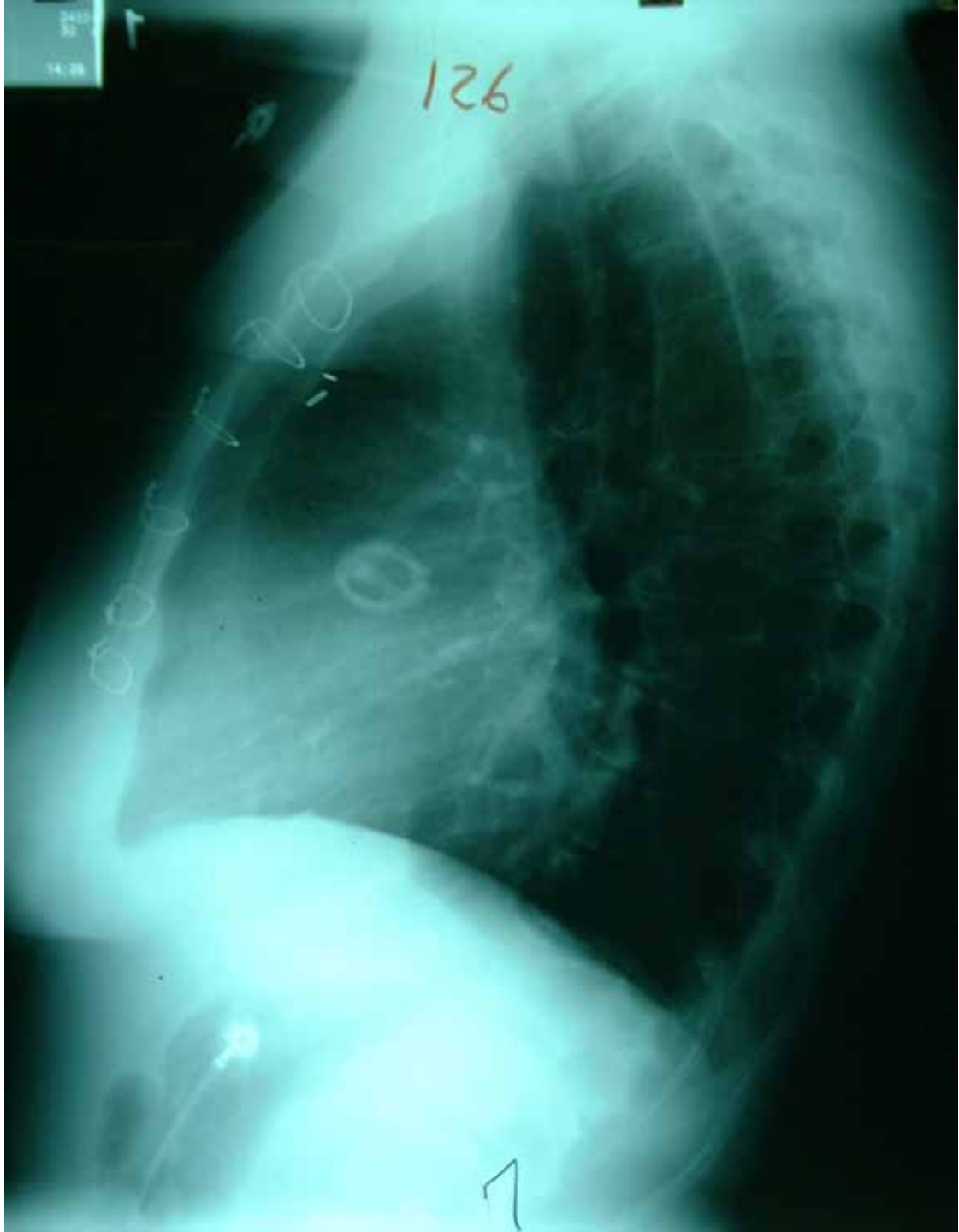




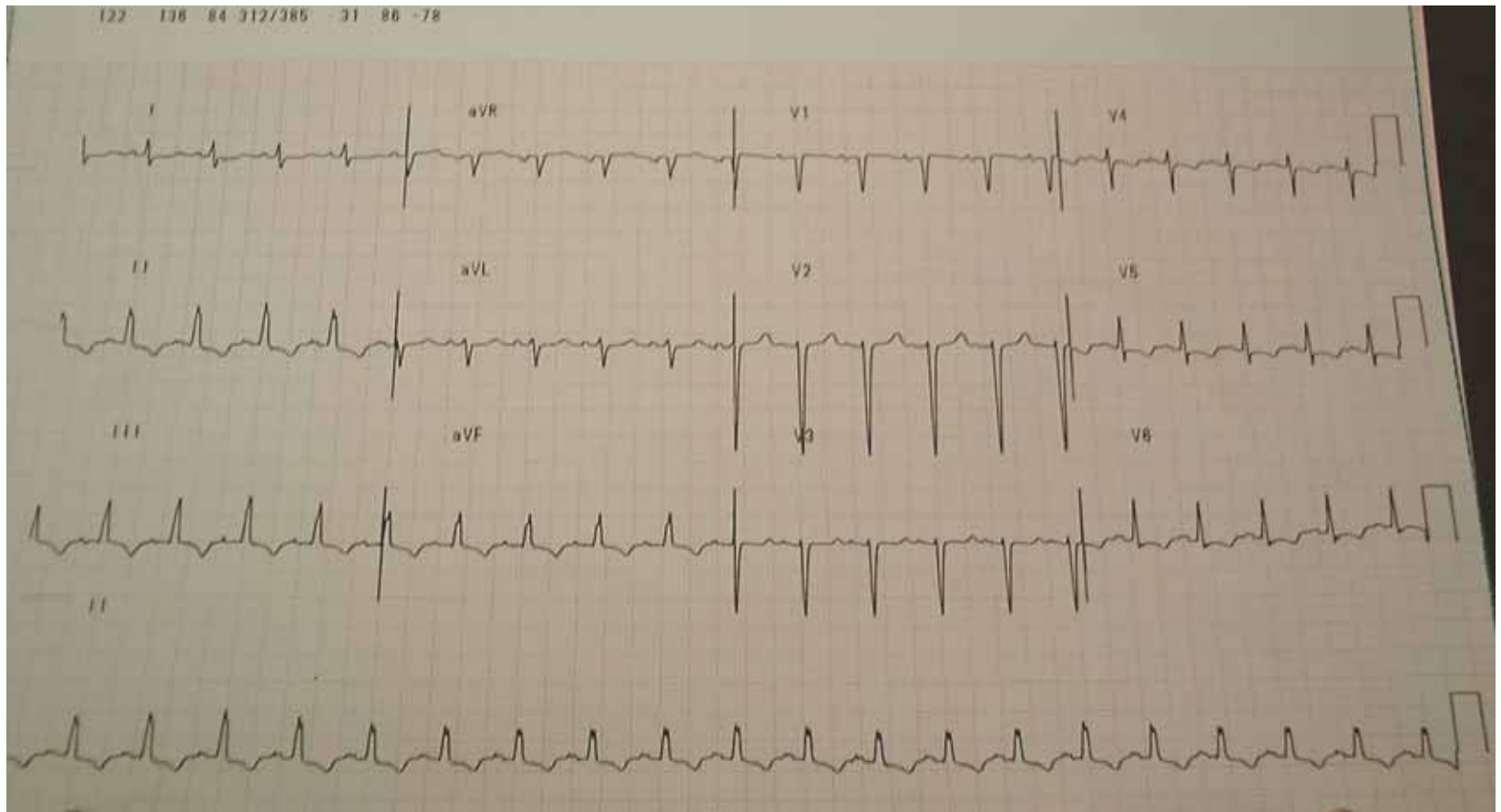


Post-RVA tachycarde 110/min





45 ans post RVA de 3 semaines, dyspnée à l'urgence



C-C+
AR-00
0:48.87

FIELD: FC
THICK: 10
INDEX: 1
kV: 120
mA: 150
PITCH: 1.0



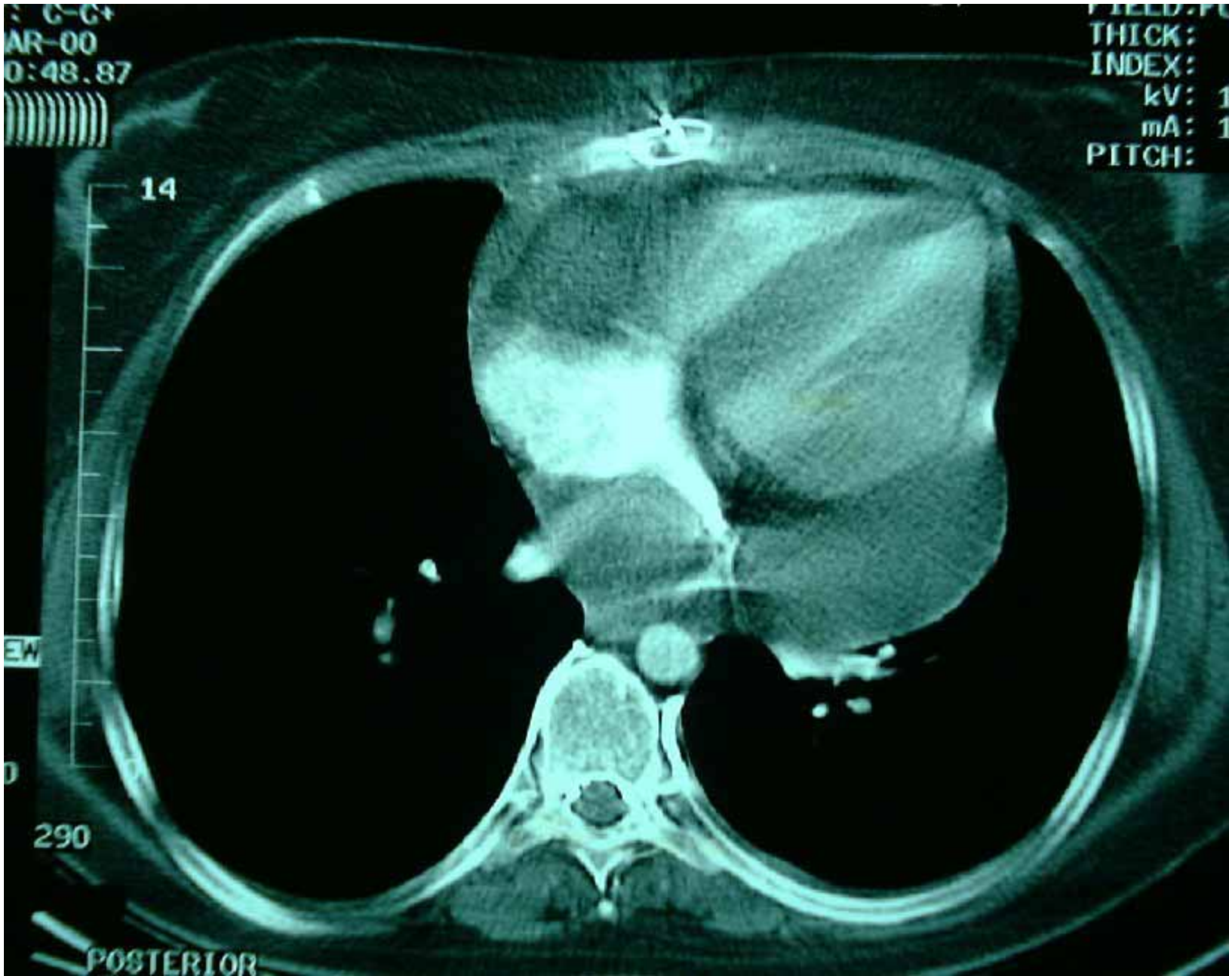
14

EW

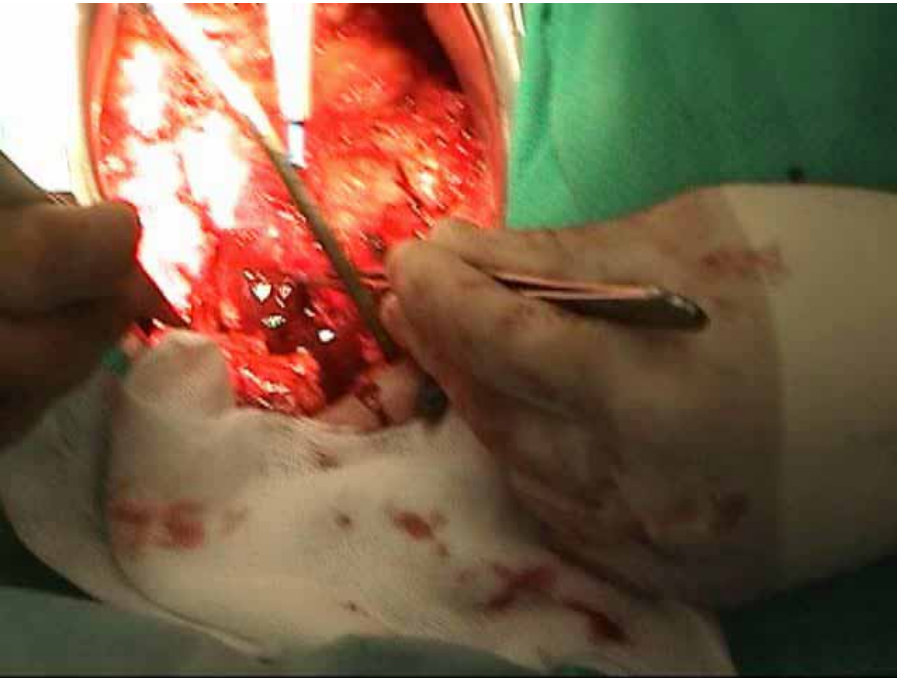
0

290

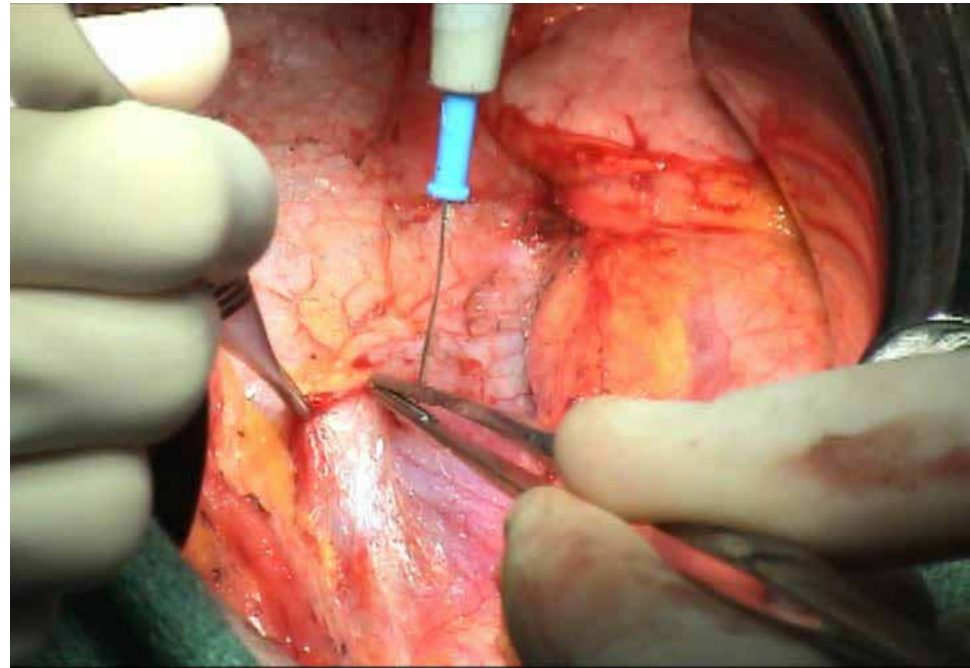
POSTERIOR



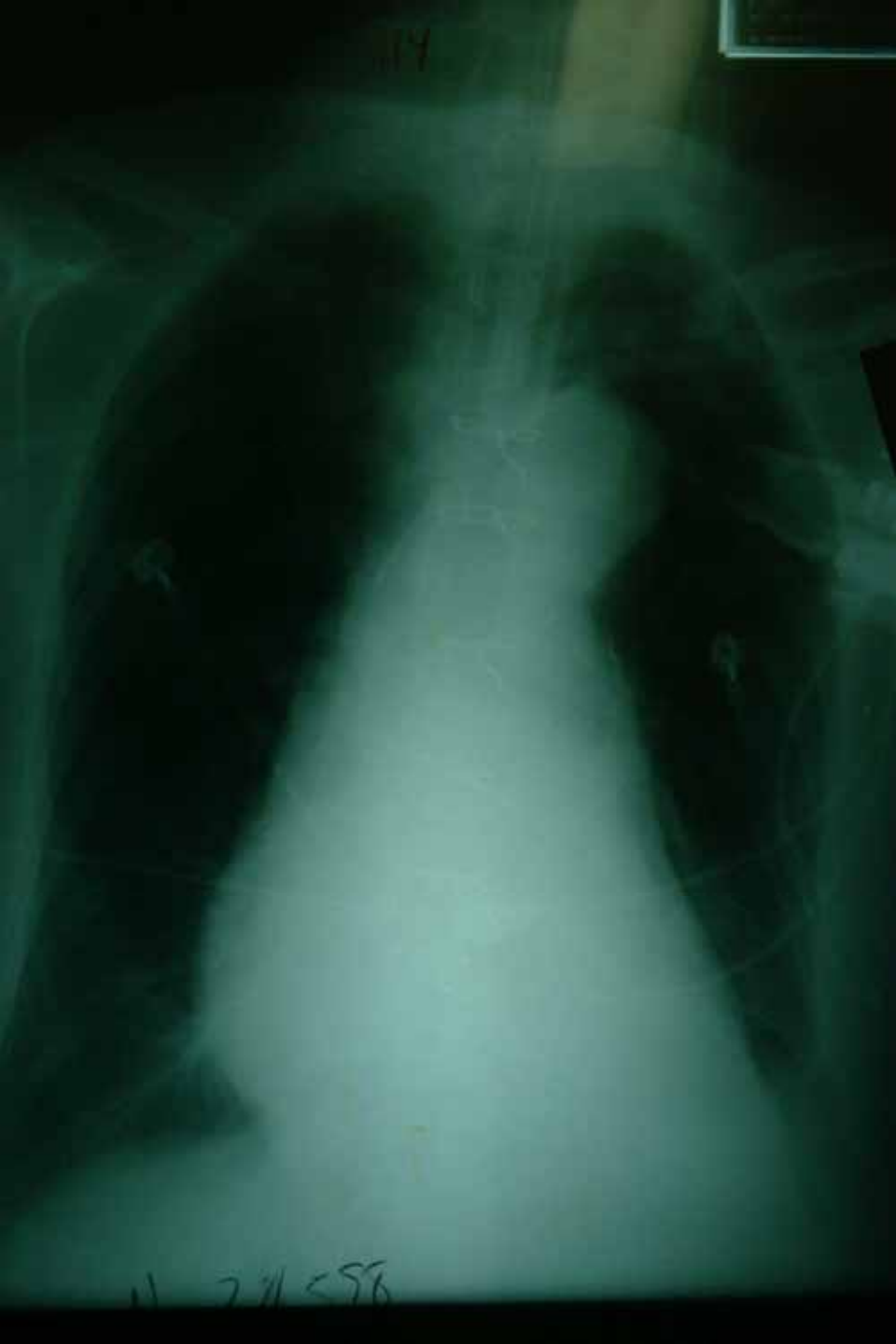Hémopéricarde



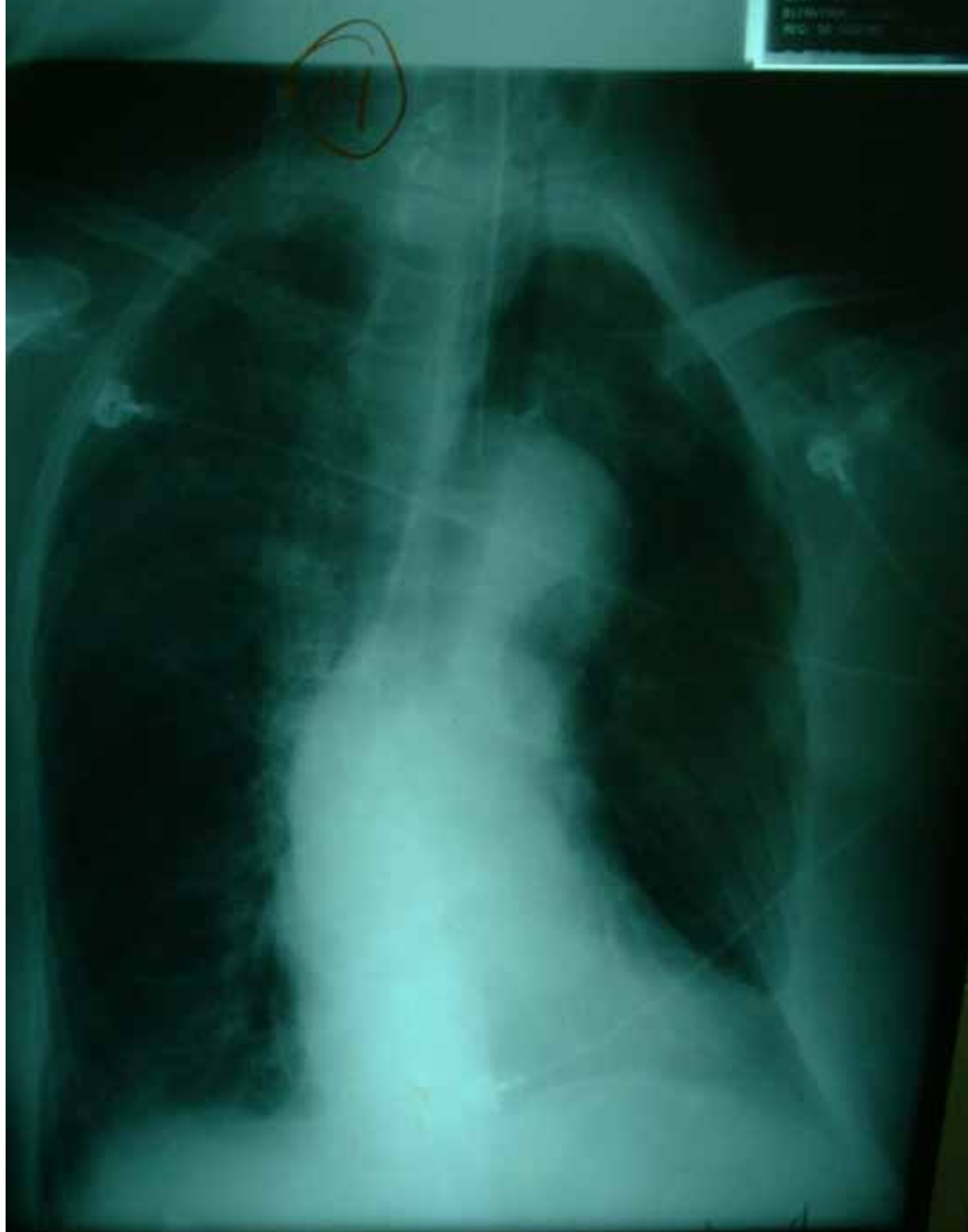Homme de 67 ans
Avant PAC et RVA
(Courtoisie Dr. Michel Pellerin)



Homme de 65 ans avant PAC
(Courtoisie Dr. Michel Pellerin)



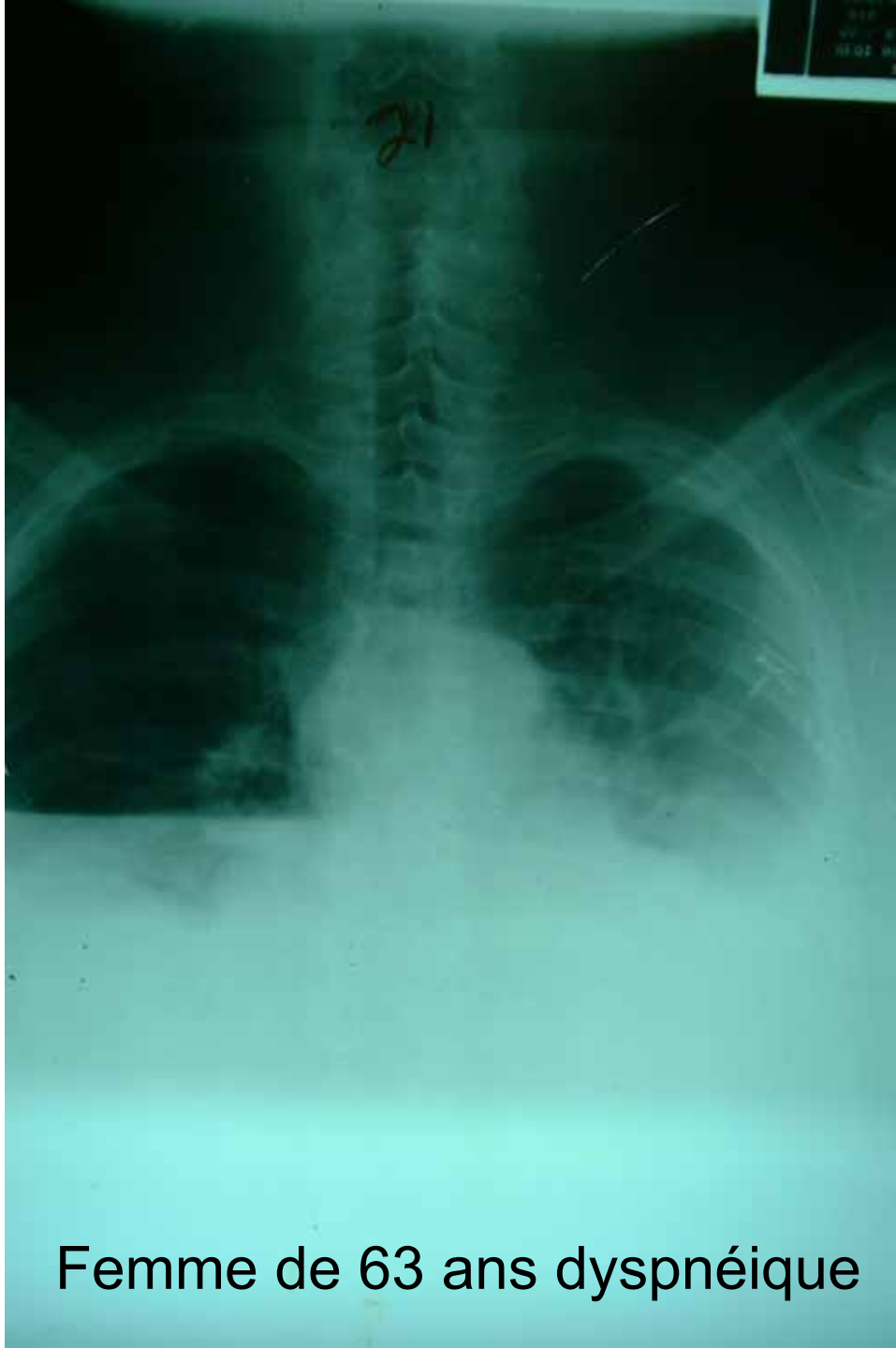Femme de 75 ans
hémiparésie gauche



Arc aortique élargi:

- athérosclérose
- insuffisance aortique
- sténose aortique
- anévrismes disséquants
- PDA

Femme de 75 ans hémiparésie gauche



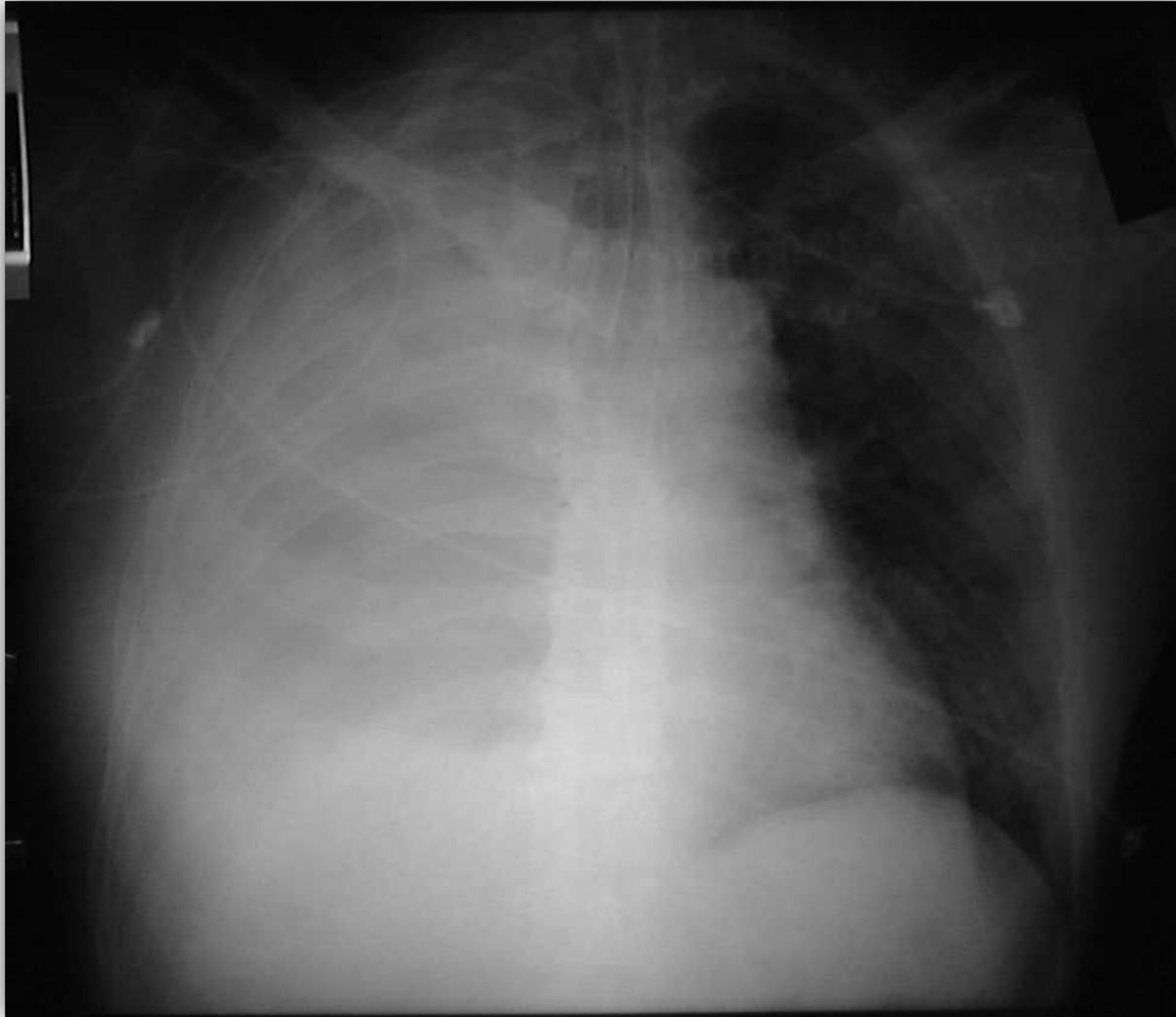
Femme de 63 ans dyspnéique

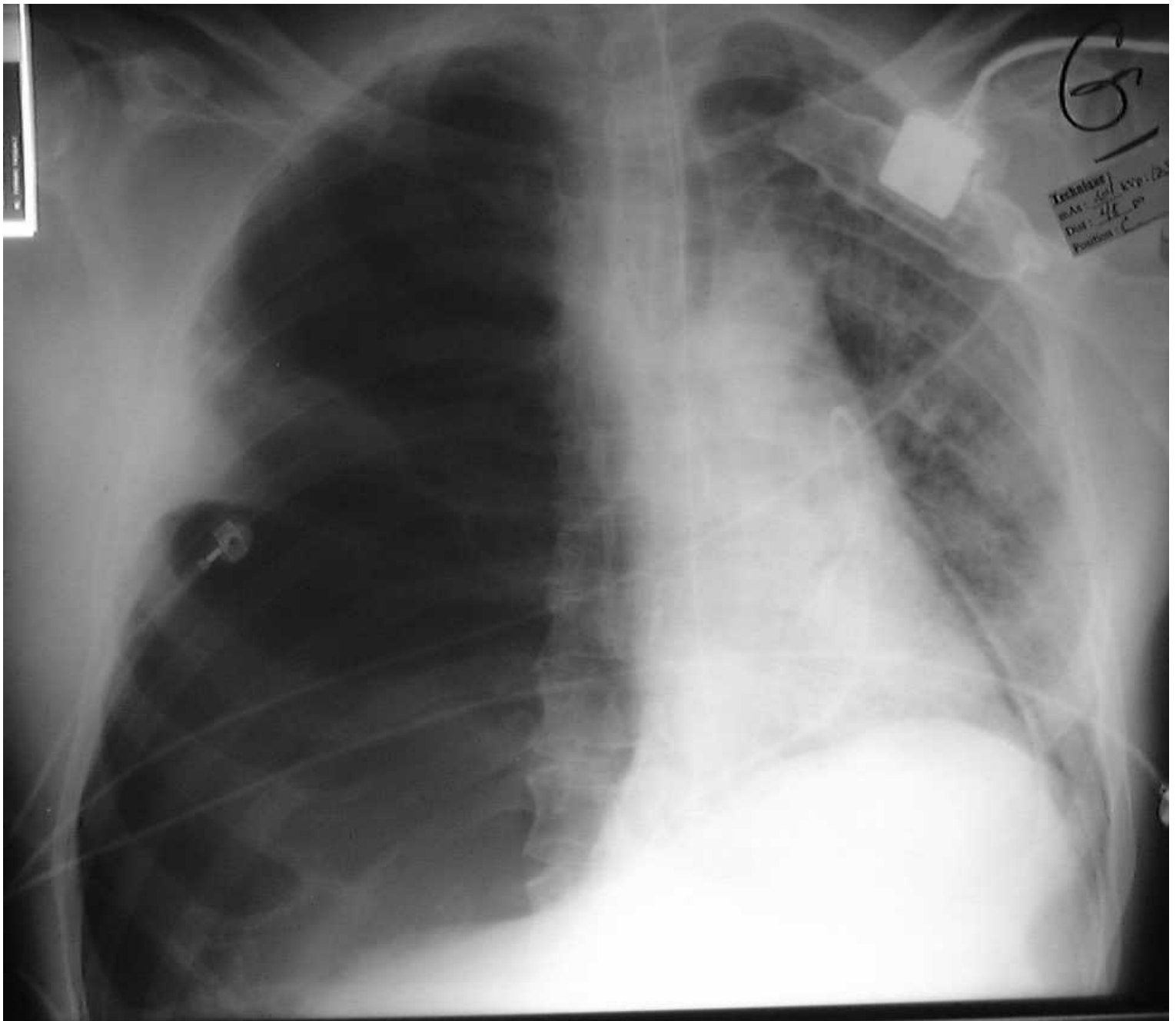
Pneumothorax:

- spontanés M:F 8:1
- iatrogénique
- traumatique
- emphysème médiastinal
- maladie pulmonaire
 - emphysème
 - pneumonie
 - néoplasie
- pneumopéritoine

Post-pneumonectomie.

Deviens soudainement très instable: levophed à 80 ml/h

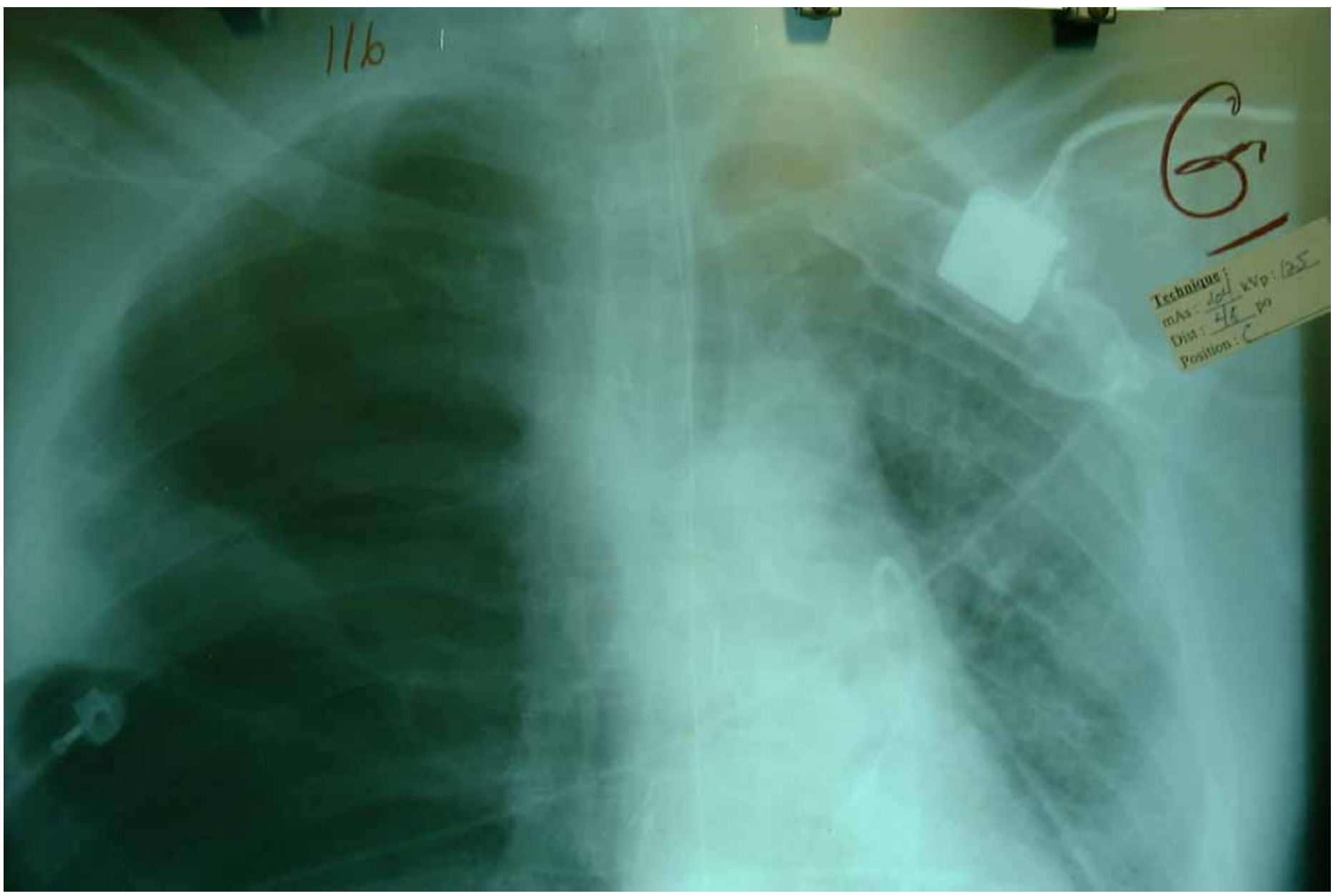


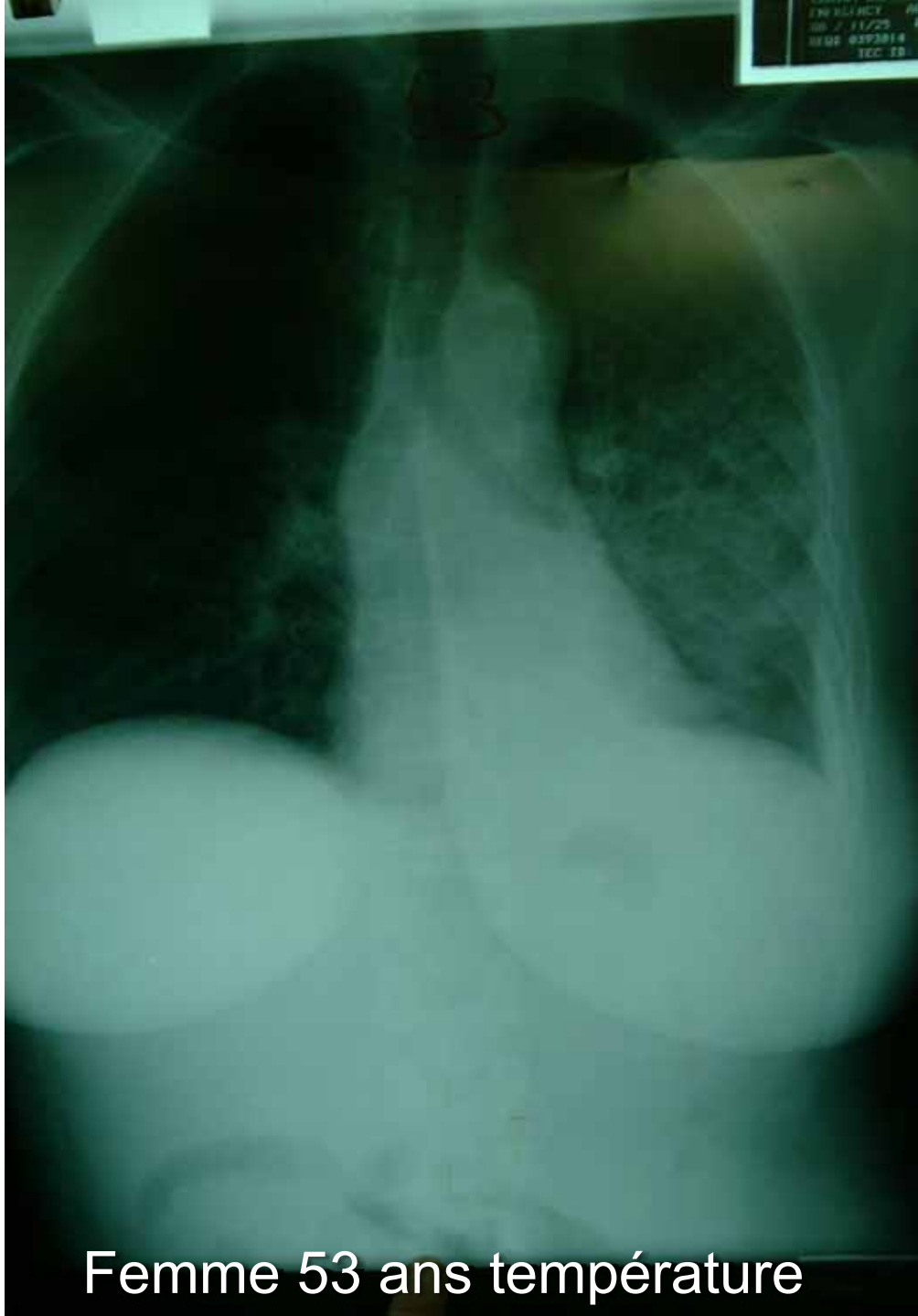


11b

G

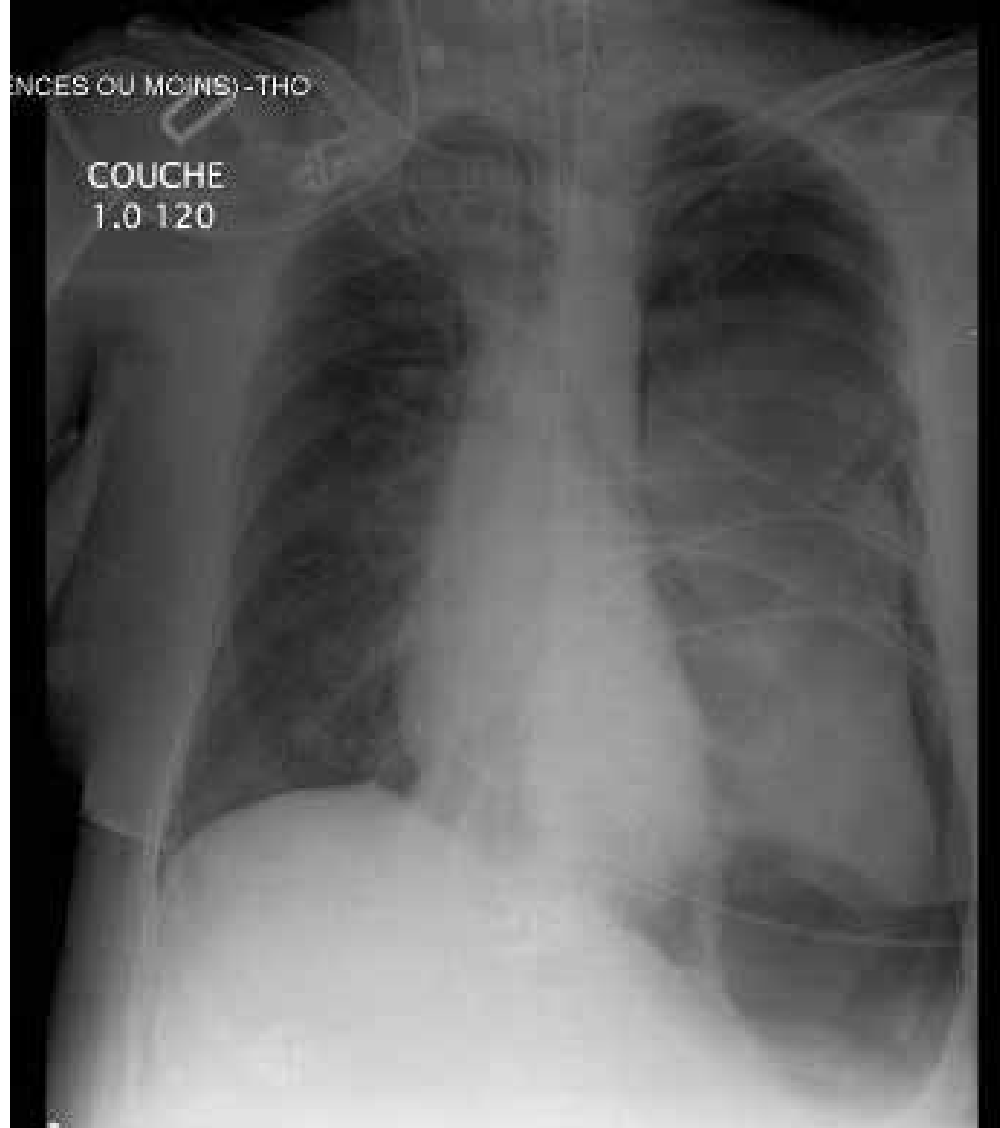
Technique:
MAS: 164 kVp: 125
Dist: 46 cm
Position: C



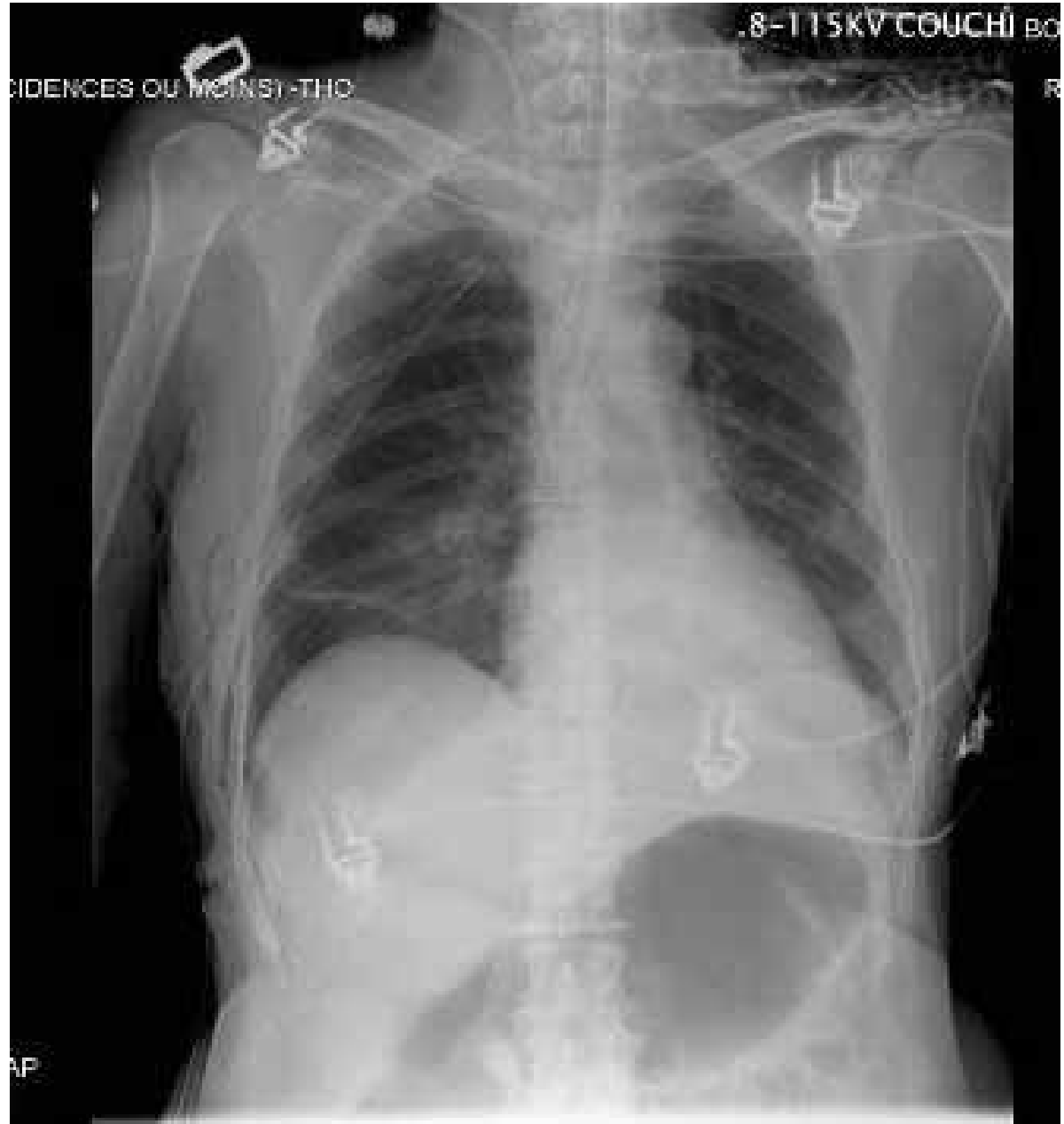
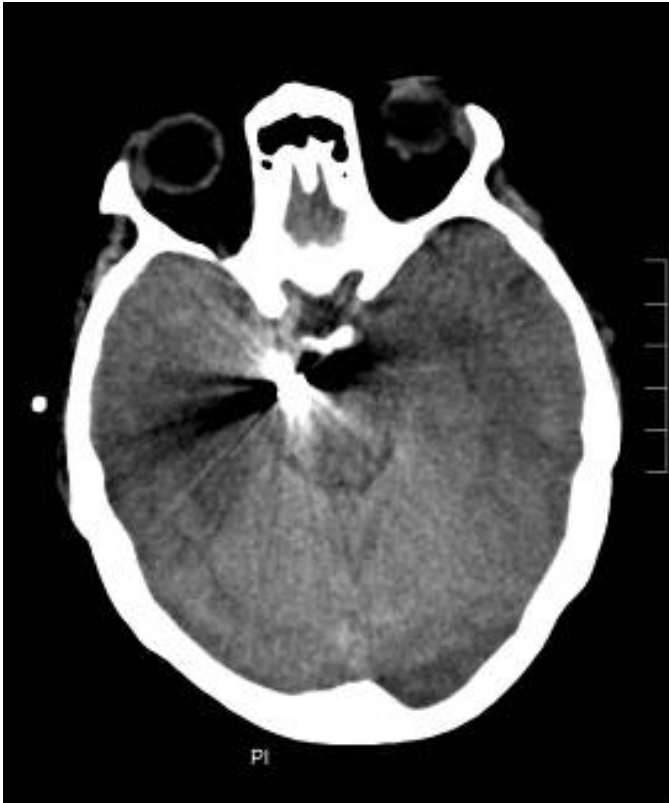
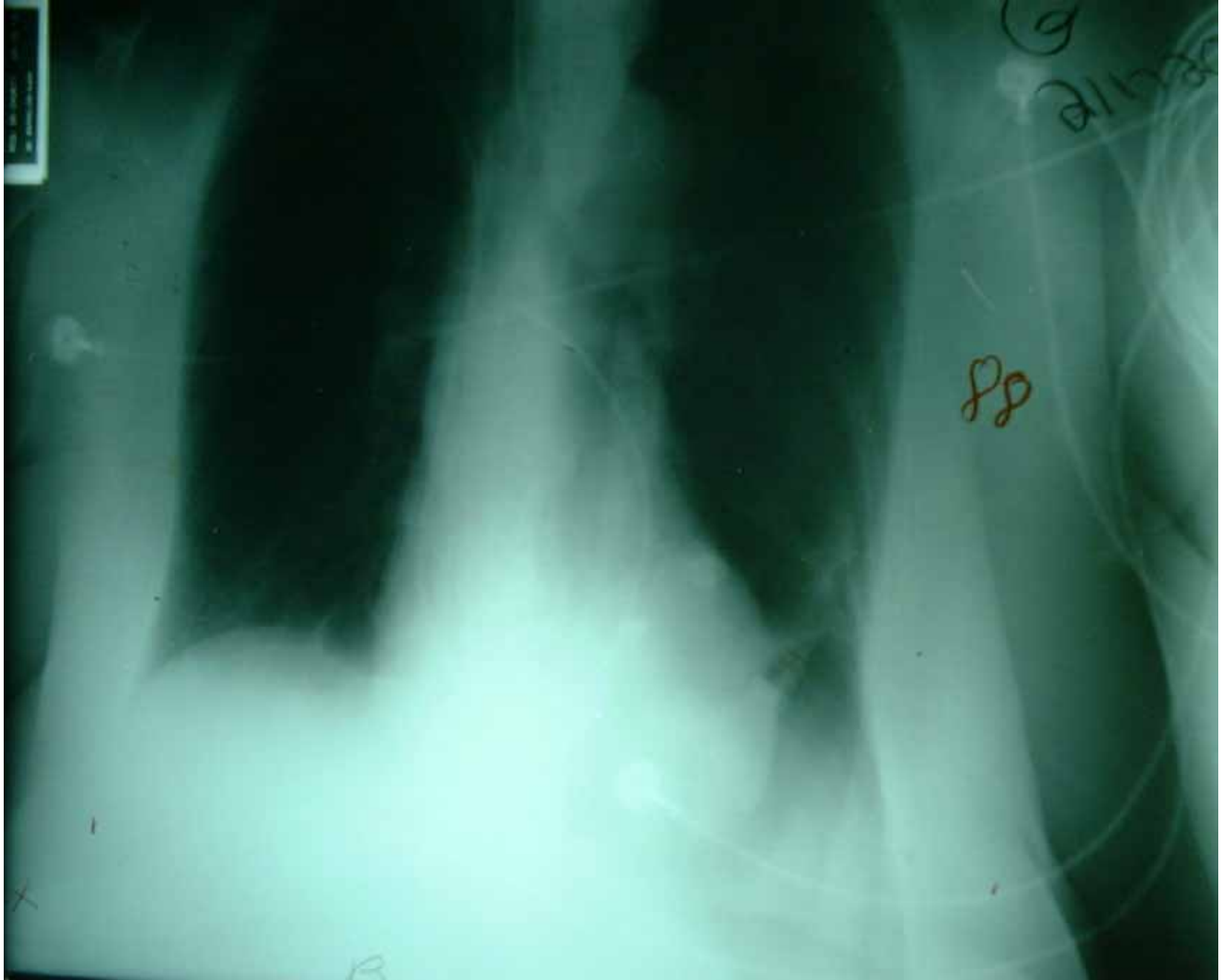
Femme 53 ans température

♀ 55 ans HSA et syndrome
cerveau-cœur: hypotension

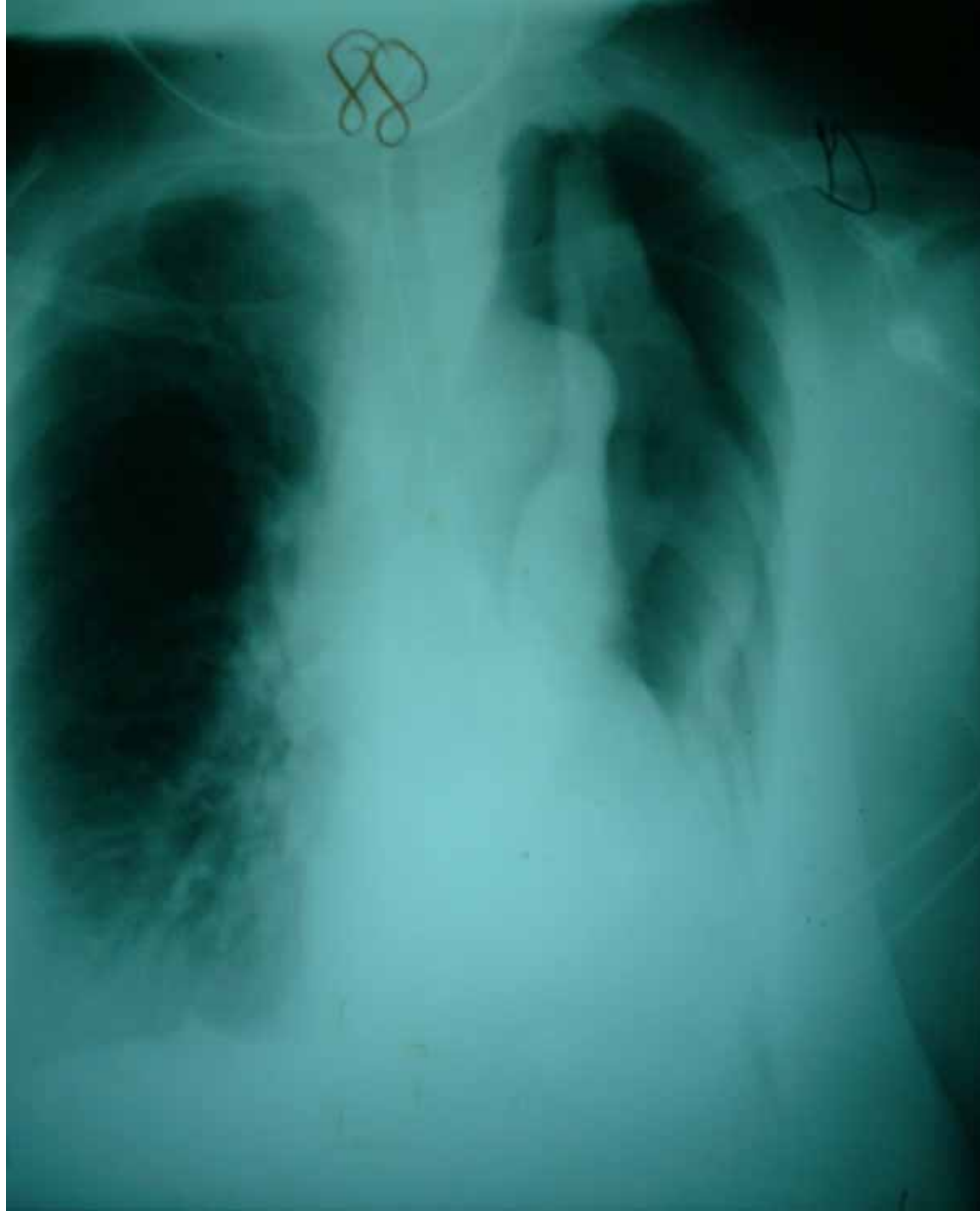


♀ 69 ans HSA





Post-op d'une femme de 62 ans néo mastoïde droite



Homme de 64 ans dyspnée après retrait de drains médiastinaux

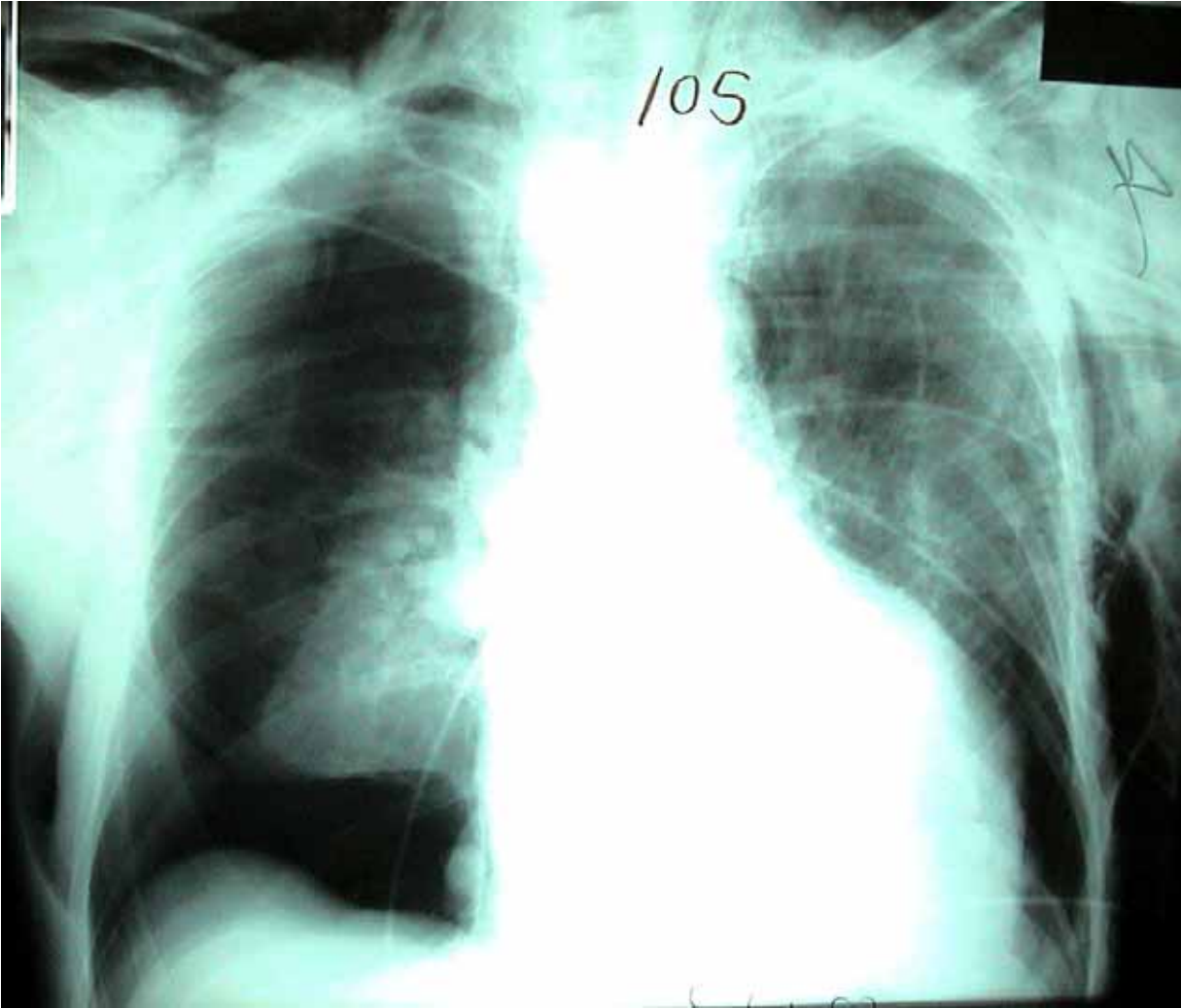
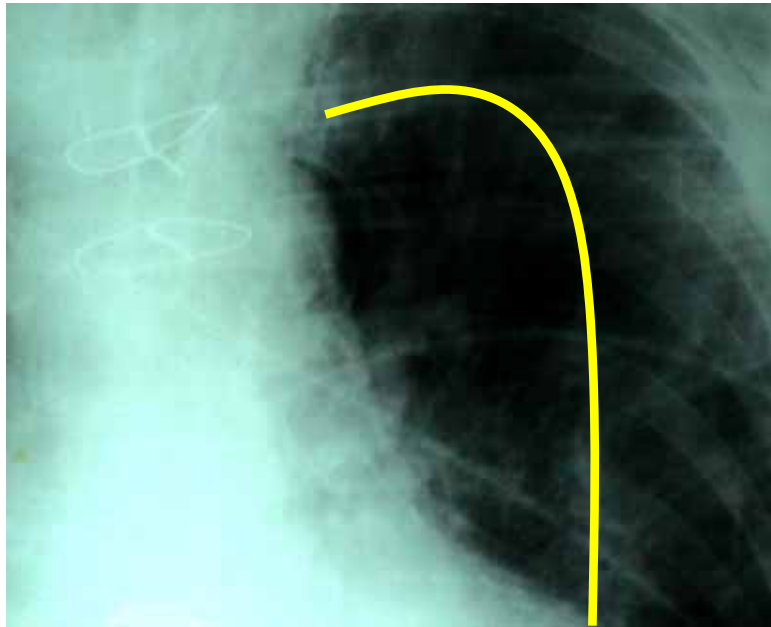


Image initiale



Post-drainage

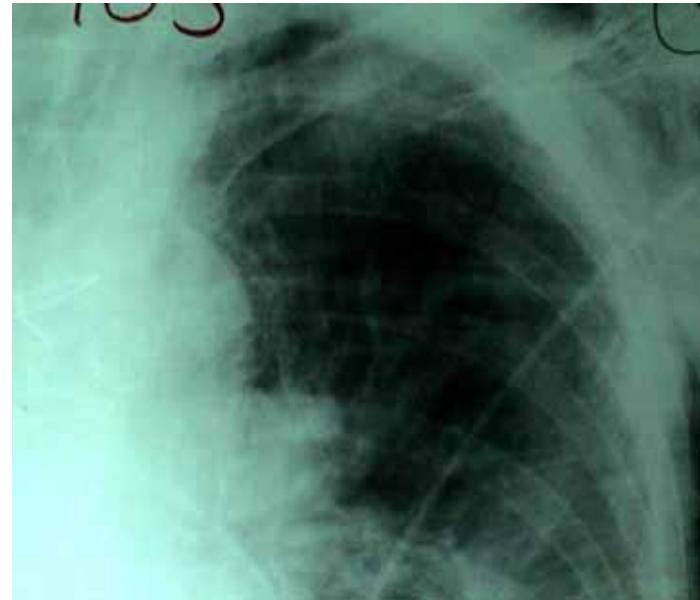
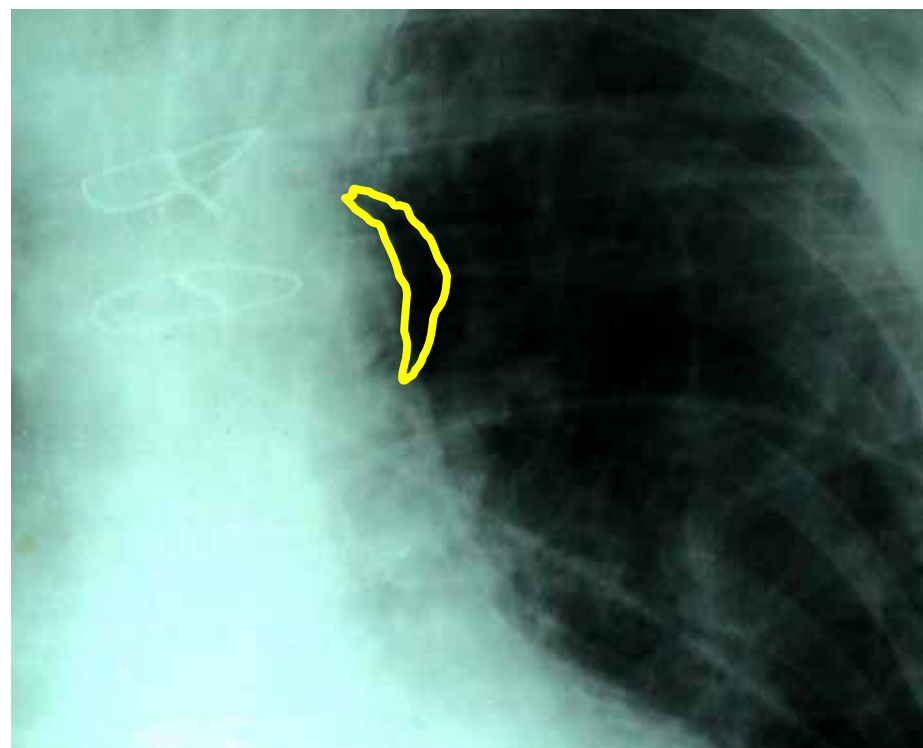
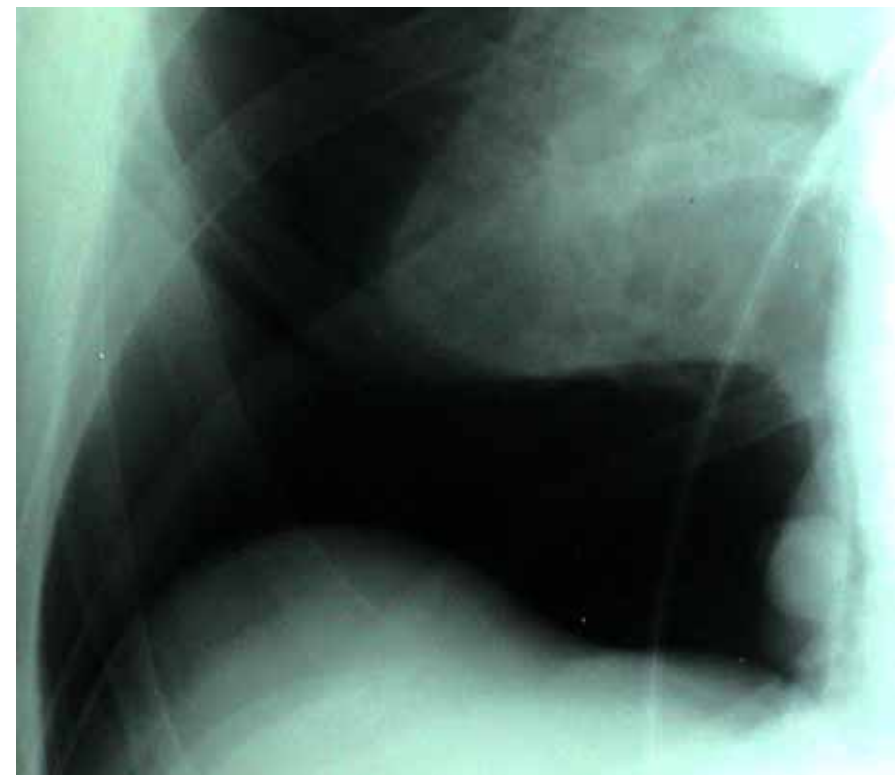
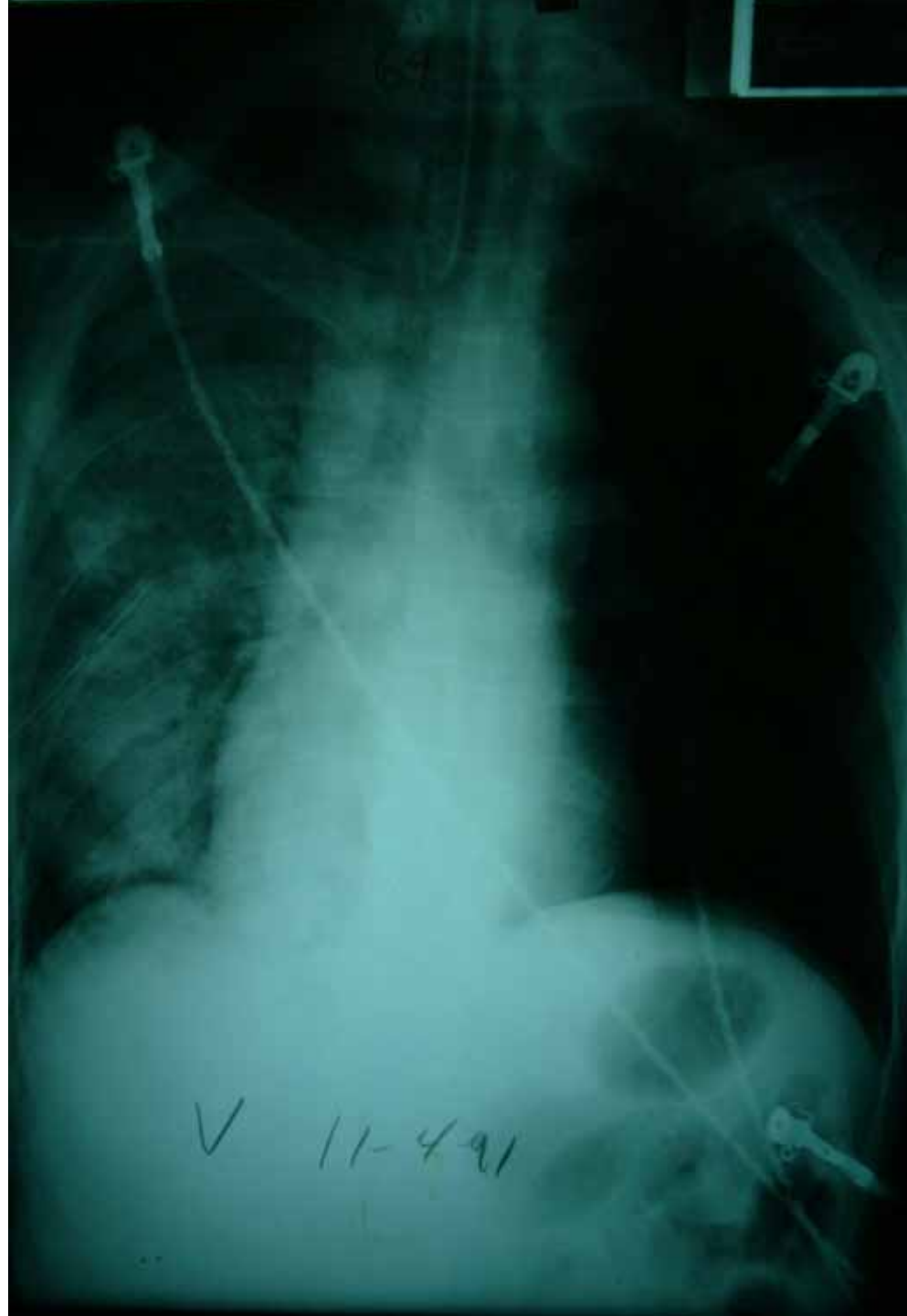
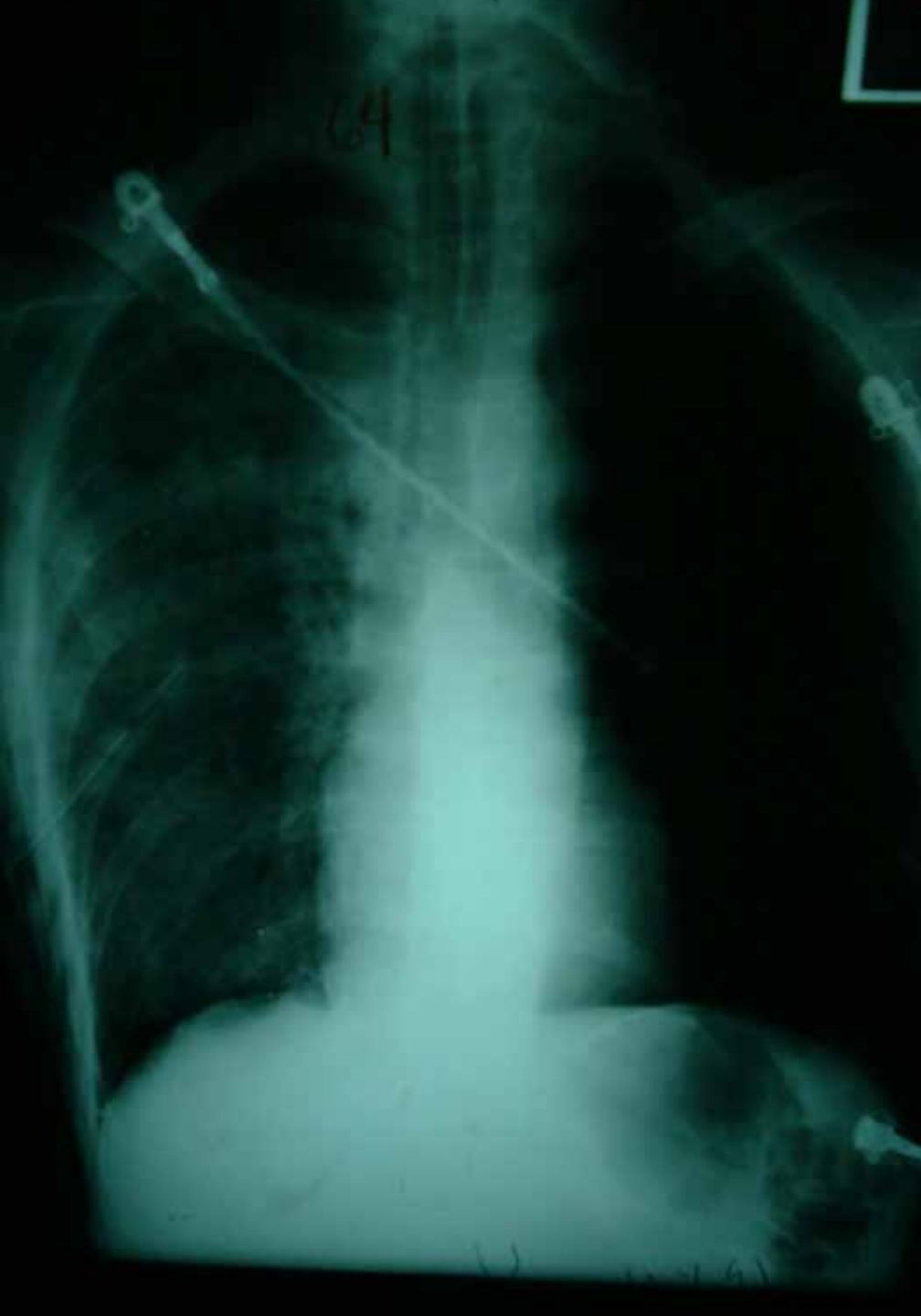

Image initiale



40 ans post
drainage de
pneumothorax
droit: demeure
dyspnéique?

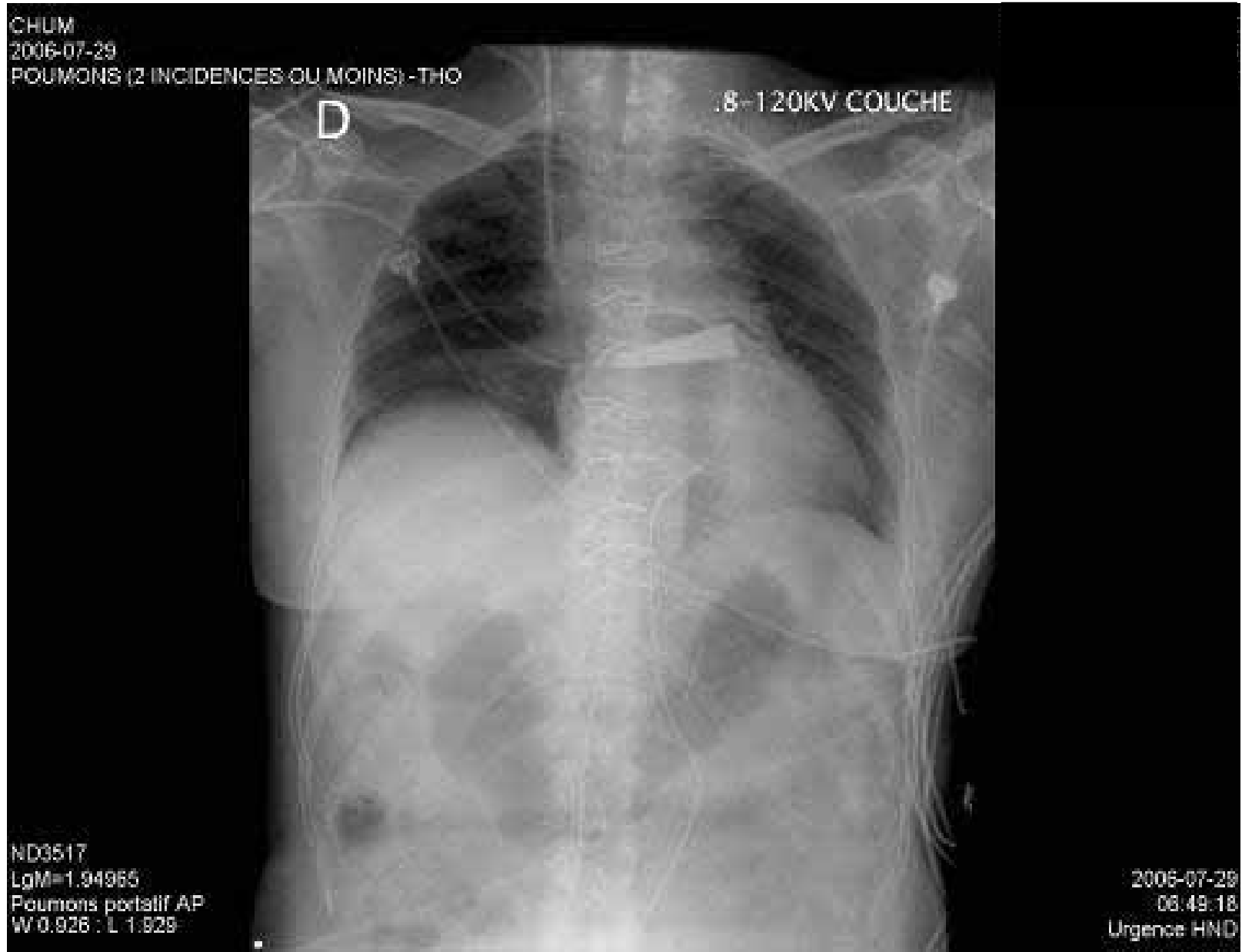



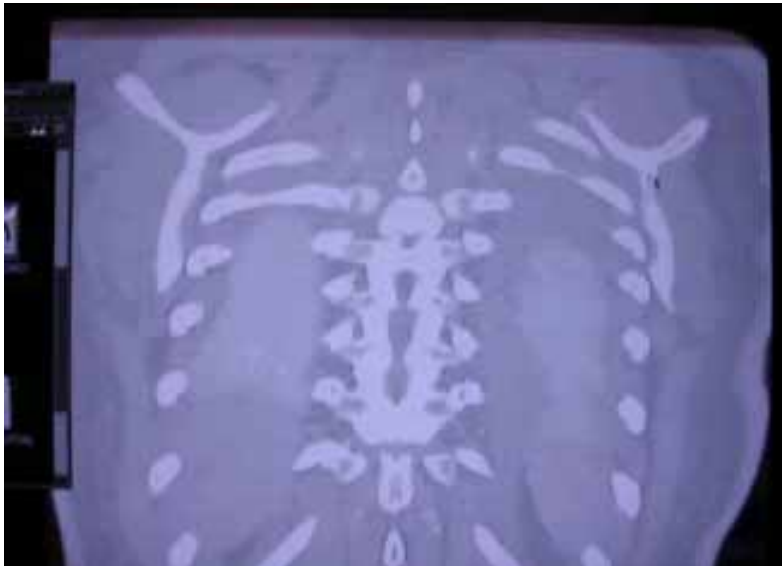
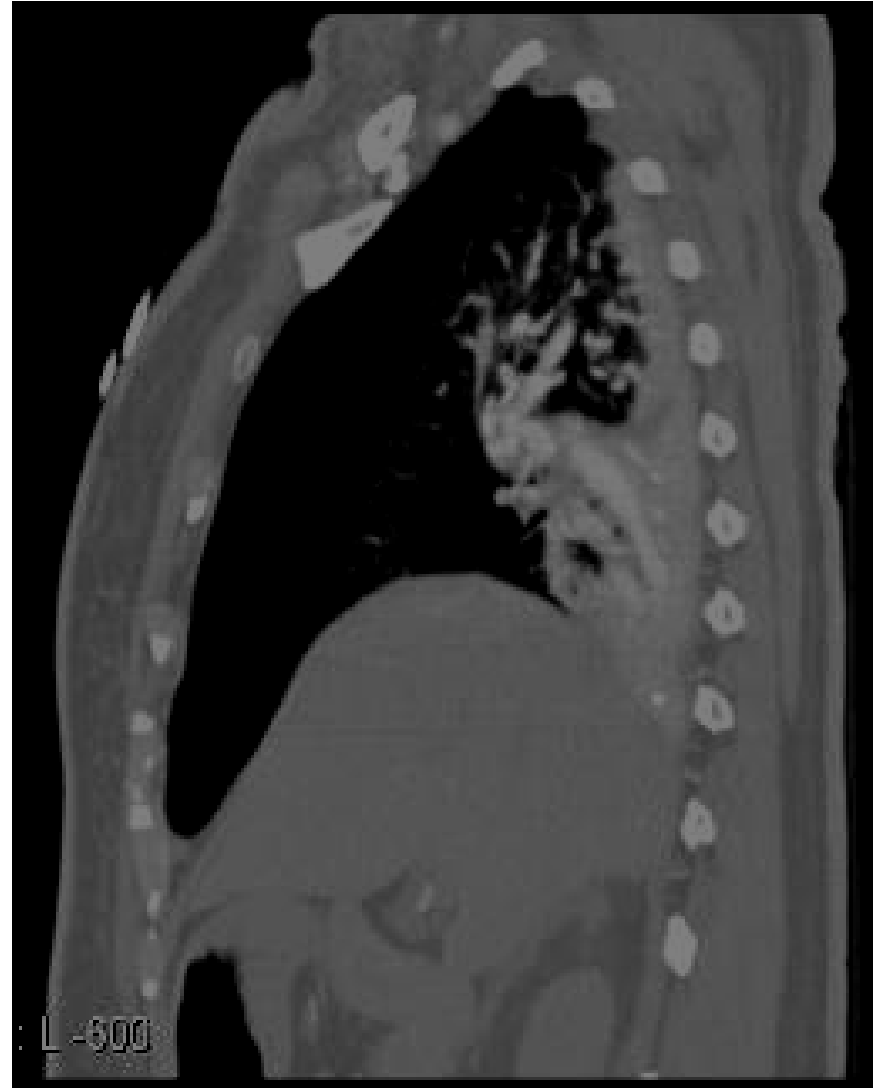
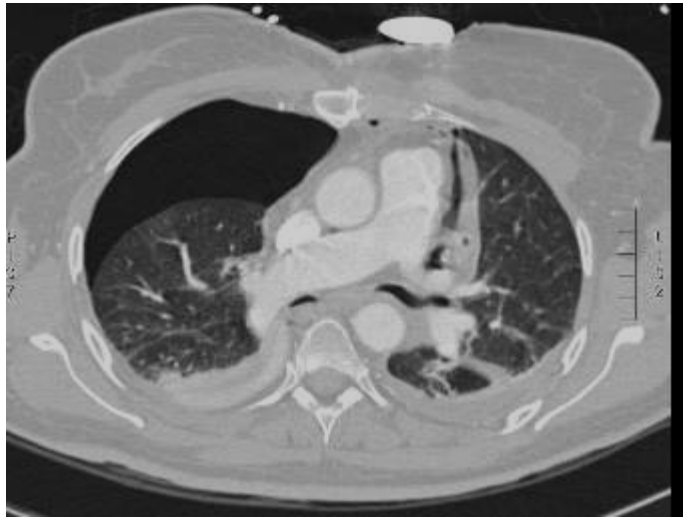Oedème pulmonaire unilatéral

- aspiration unilatérale
- contusion pulmonaire
- thoracocentèse rapide
- obstruction bronchique
- décubitus latéral prolongé

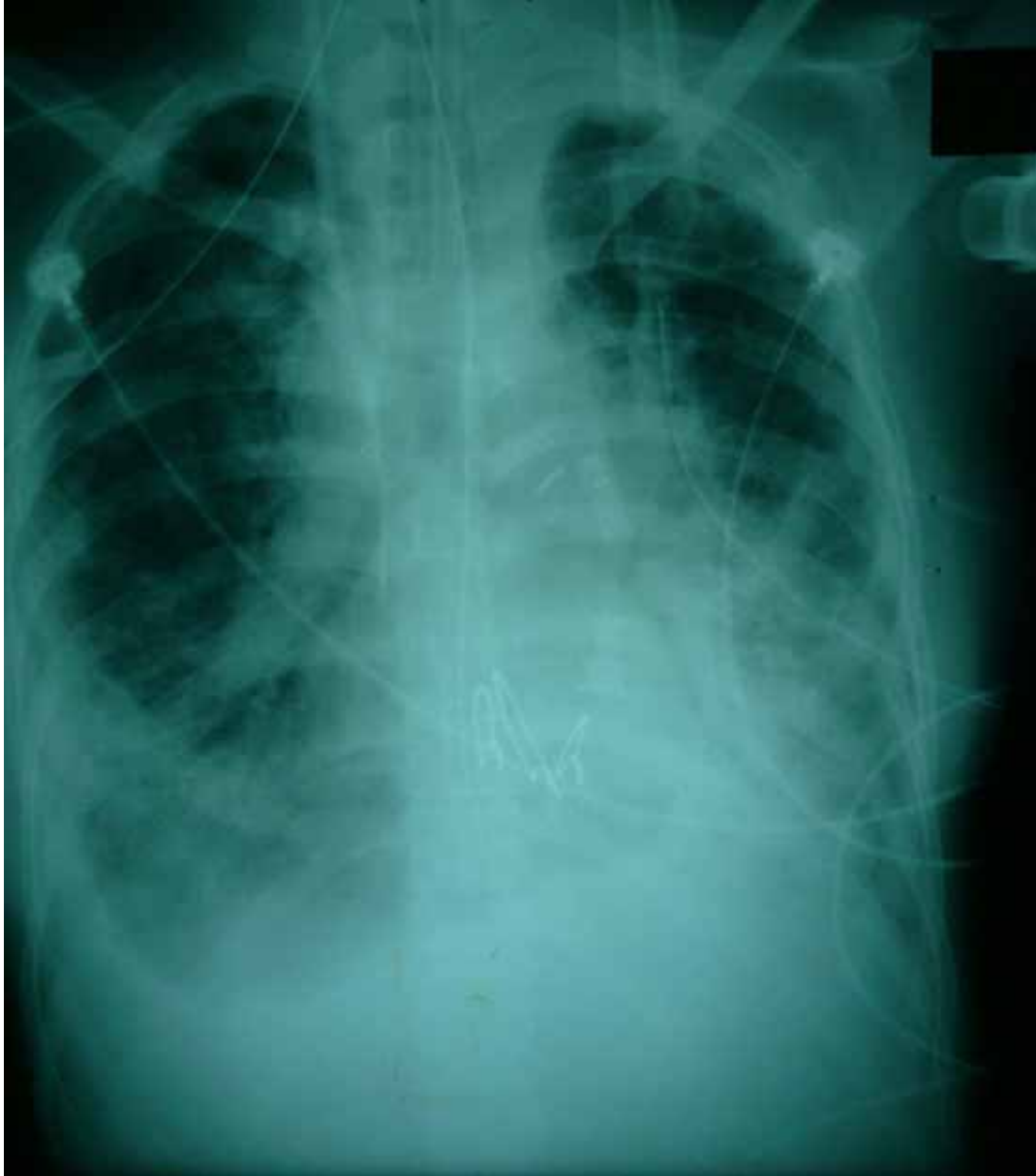
♀ 59 ans post PAC: désaturation



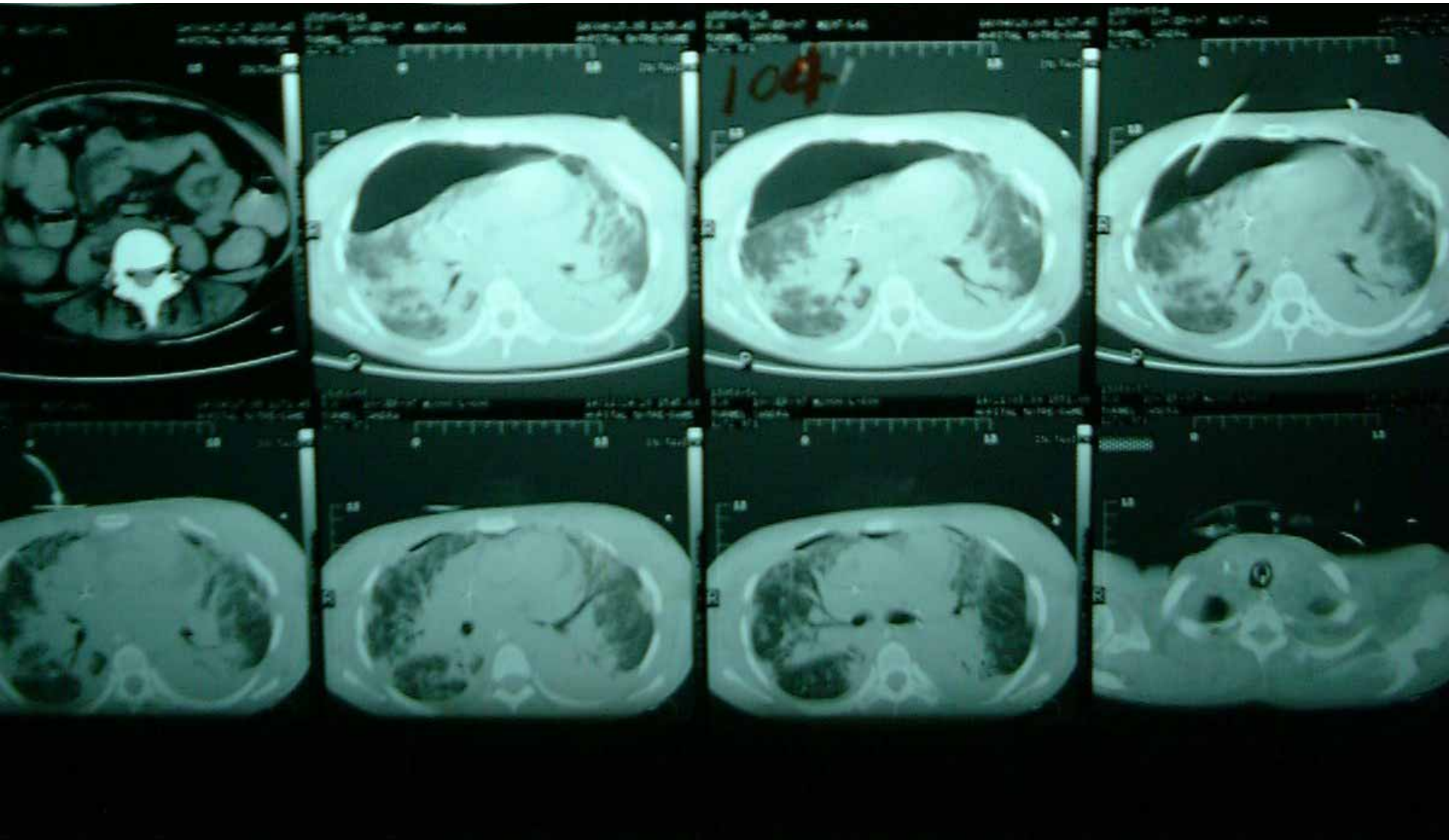
♀ 59 ans désaturation post-PAC



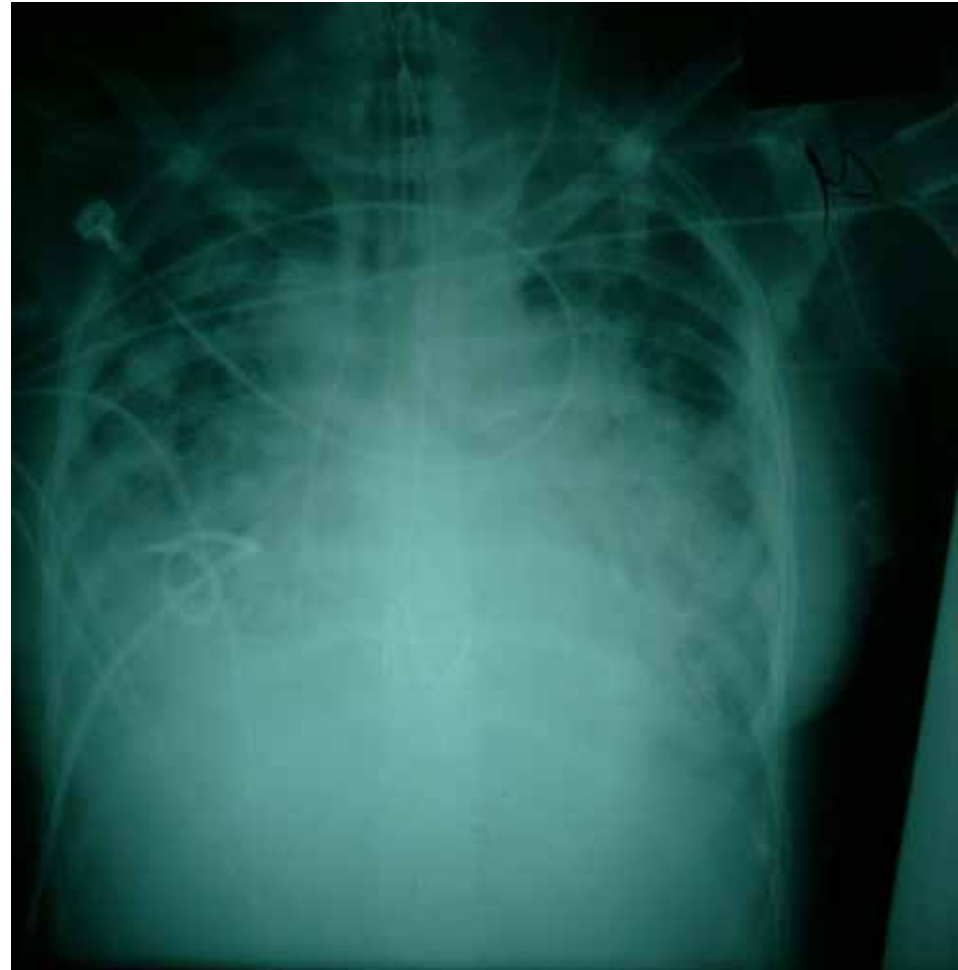
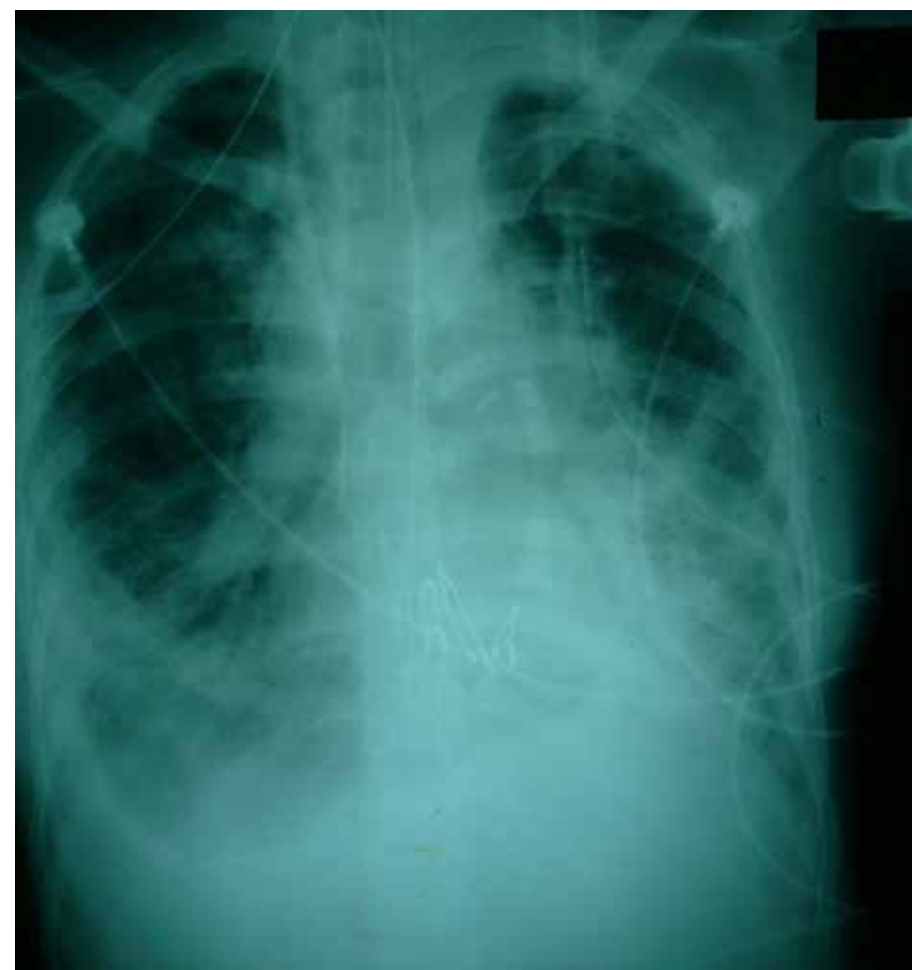
♀ 25 ans greffe pulmonaire: désaturation?



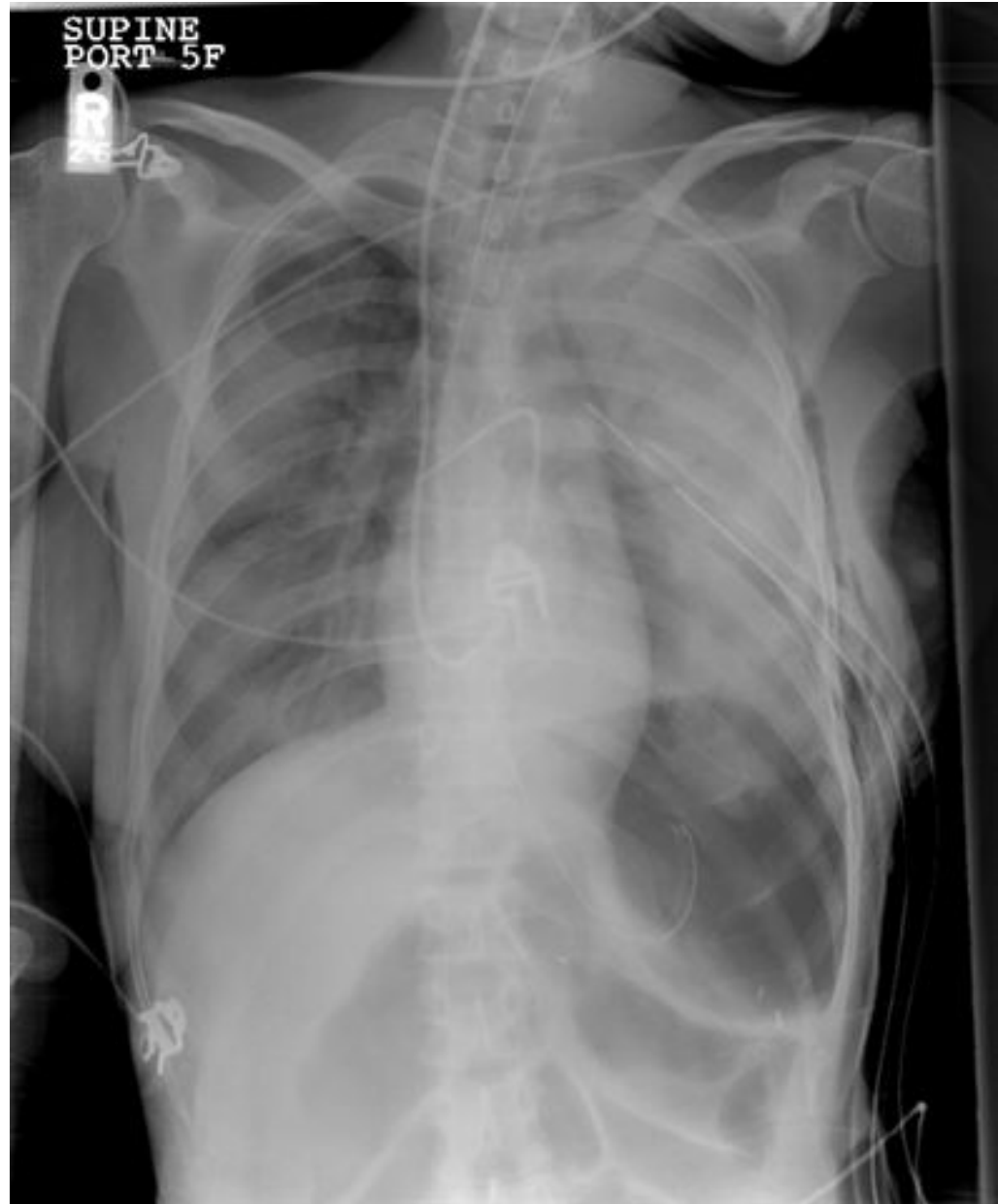CTSCAN



Avant et après “pigtail”



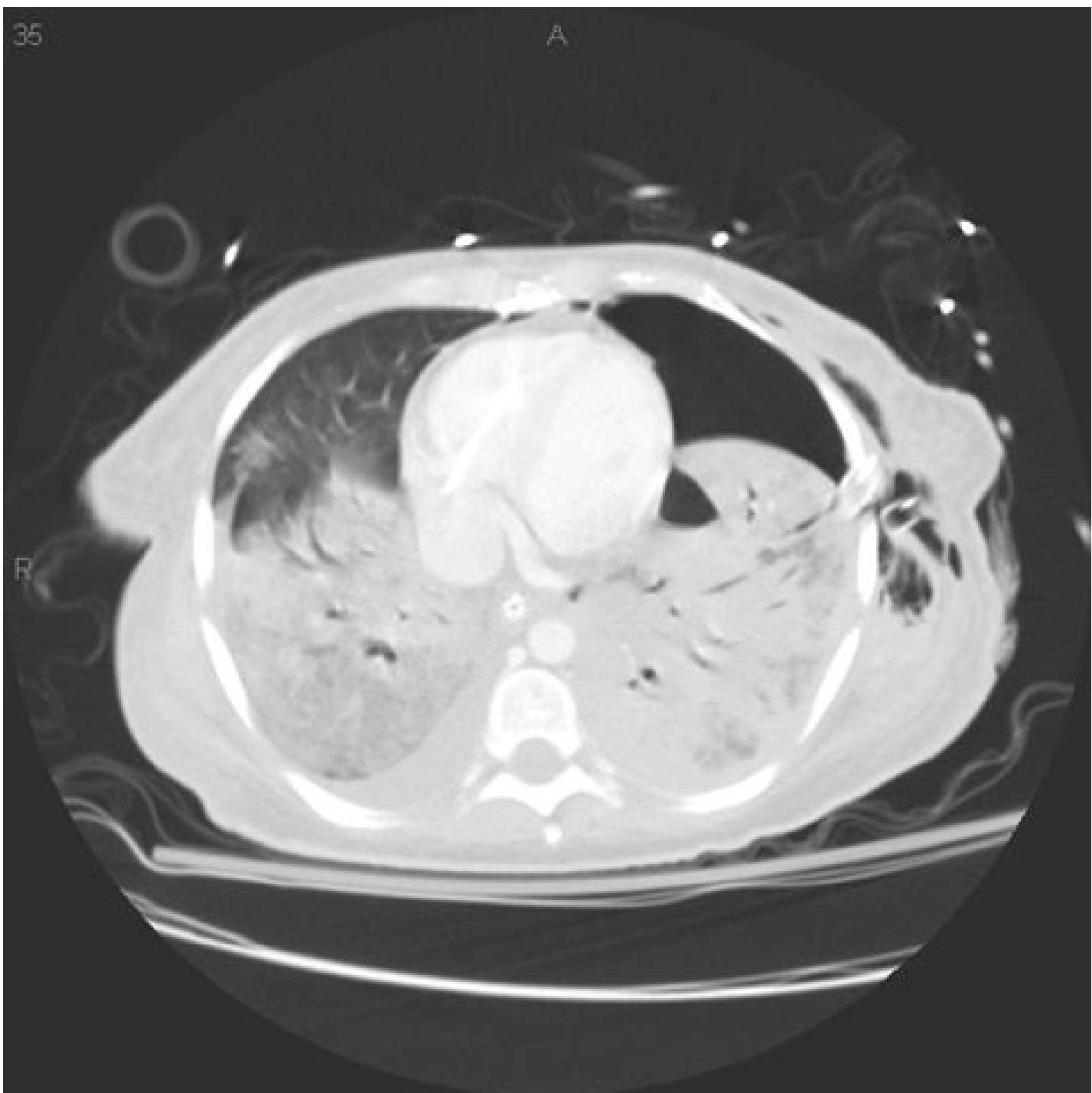
♂ 35 ans
pneumonie et
désaturation



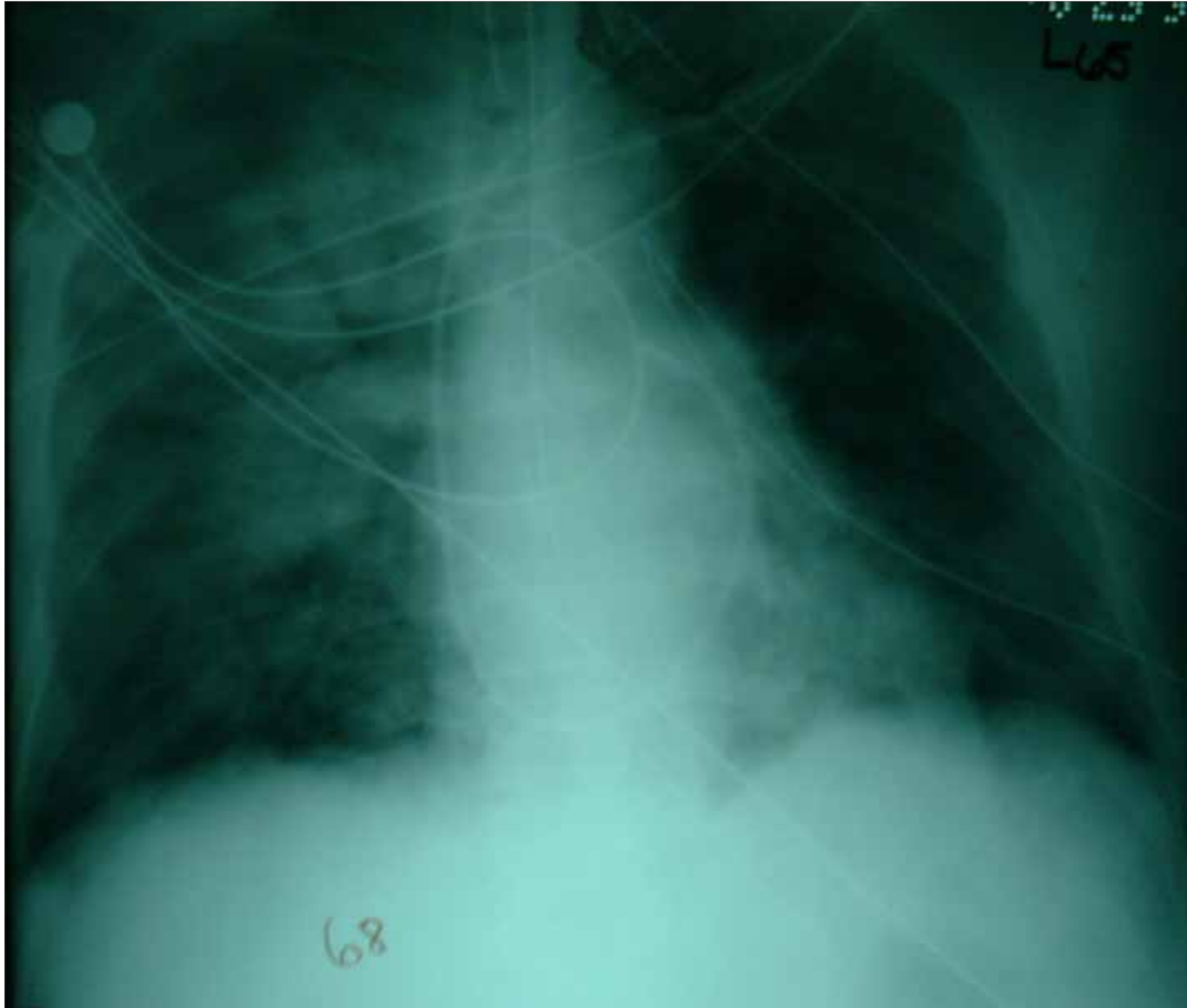
35

A

R



♂ 65 ans pneumonie et
pression de crête élevée

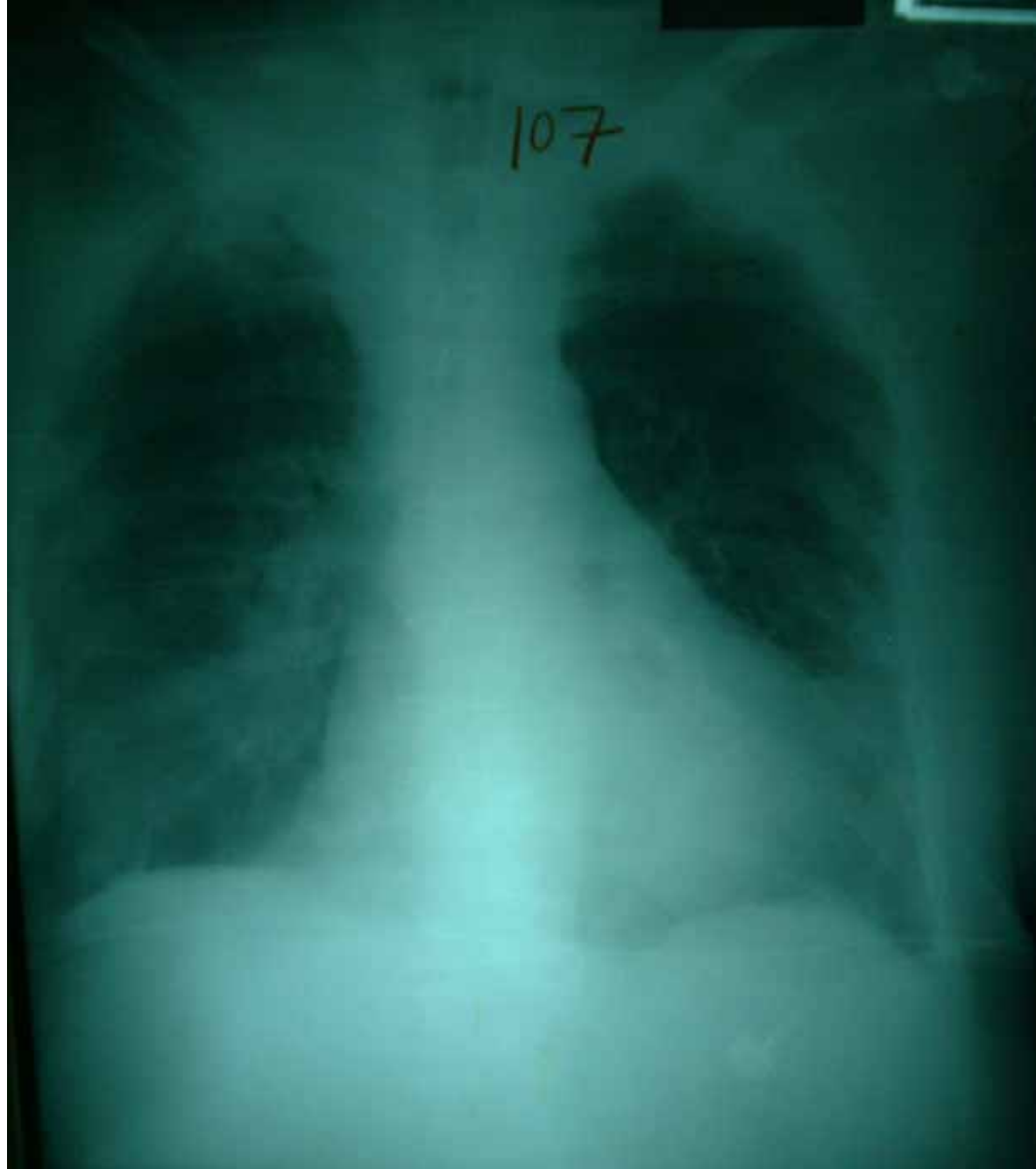


Pneumothorax antérieur:

- hypertransparence à la base du poumon
- signe profond de sulcature
- double signe du diaphragme

68

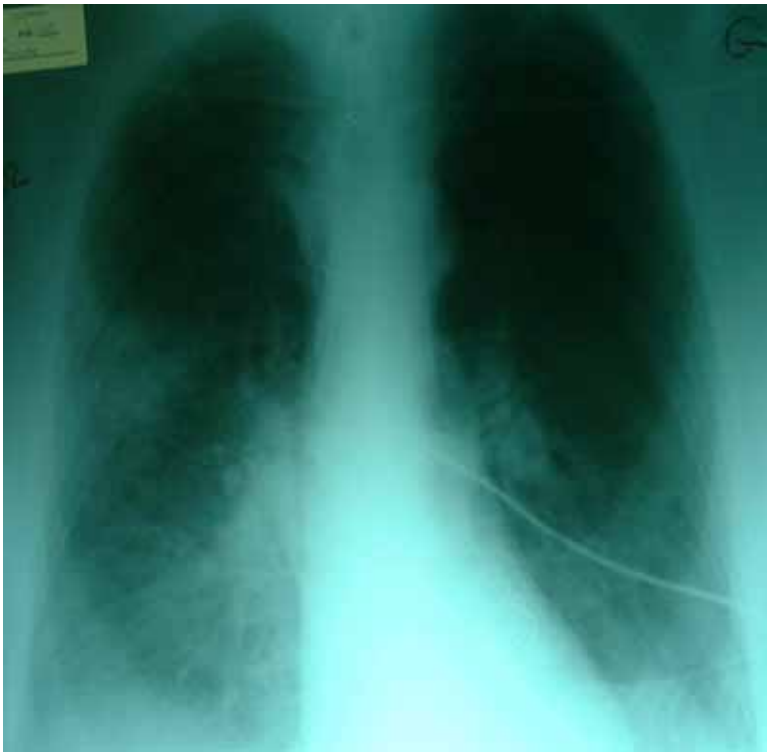♂ 65 ans pneumonie, pression de crête élevée



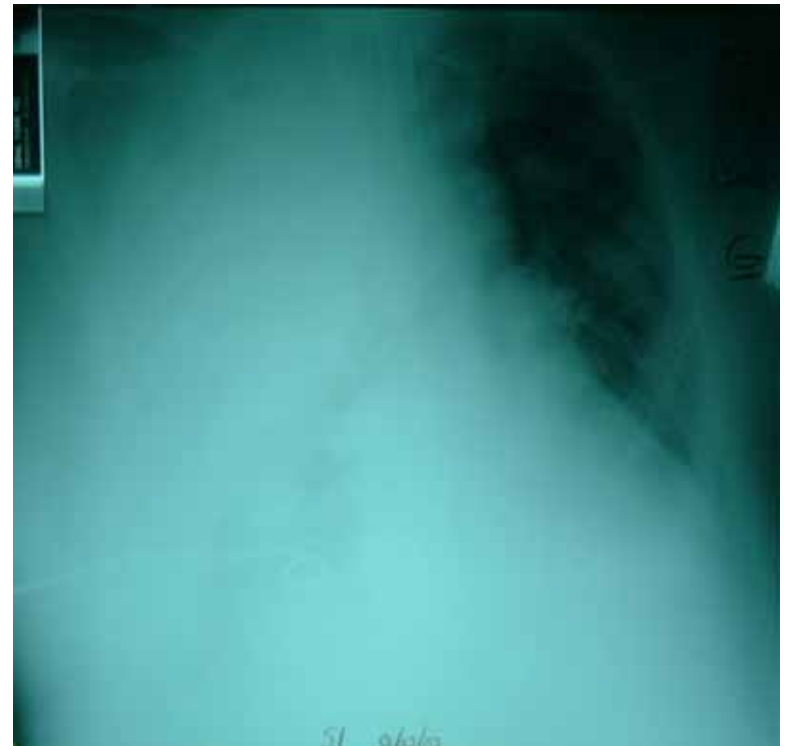
Femme de 83 ans dyspnéique post-op chx genou

Le patient est hypotendu?

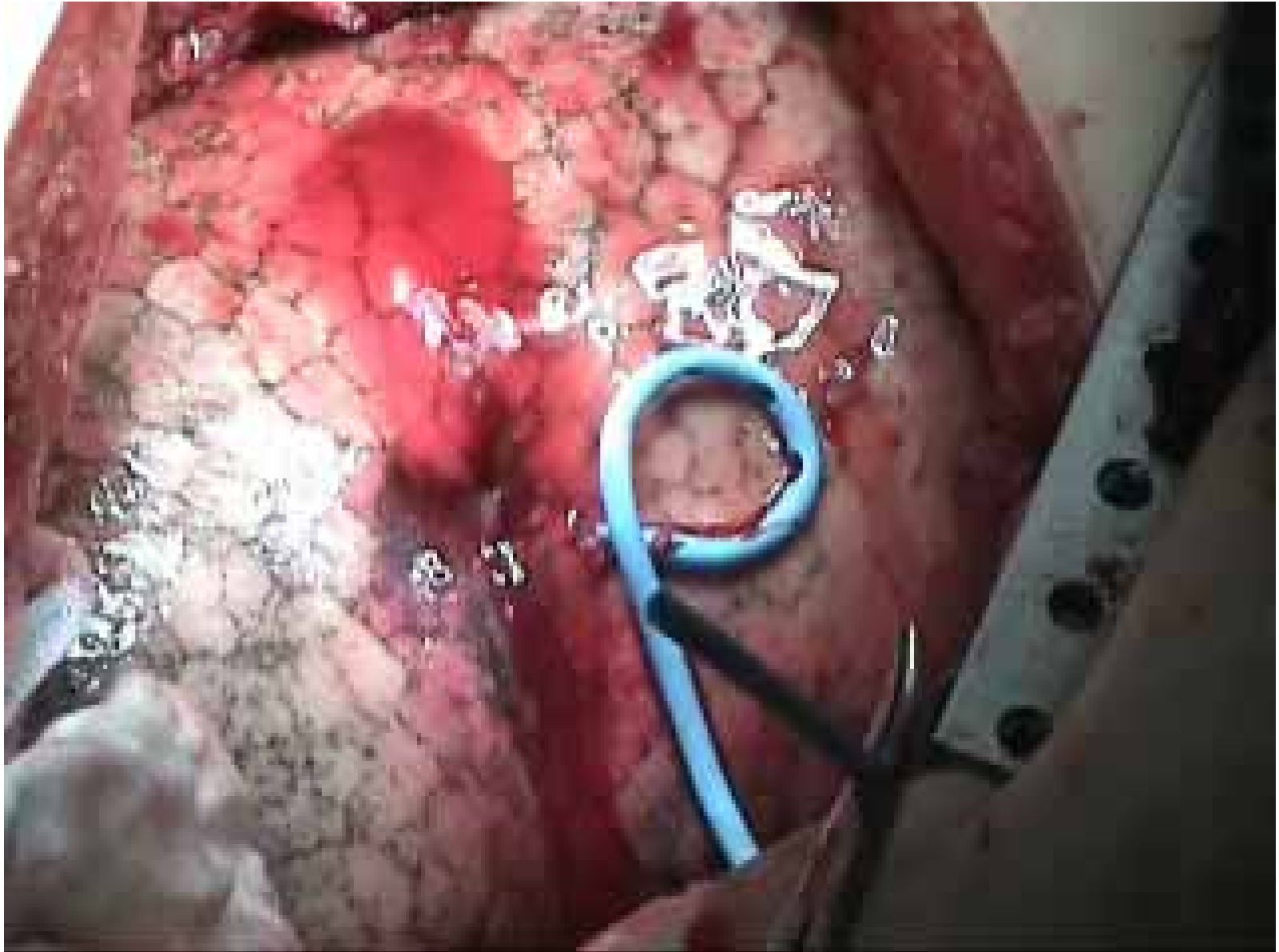Avant « pigtail »

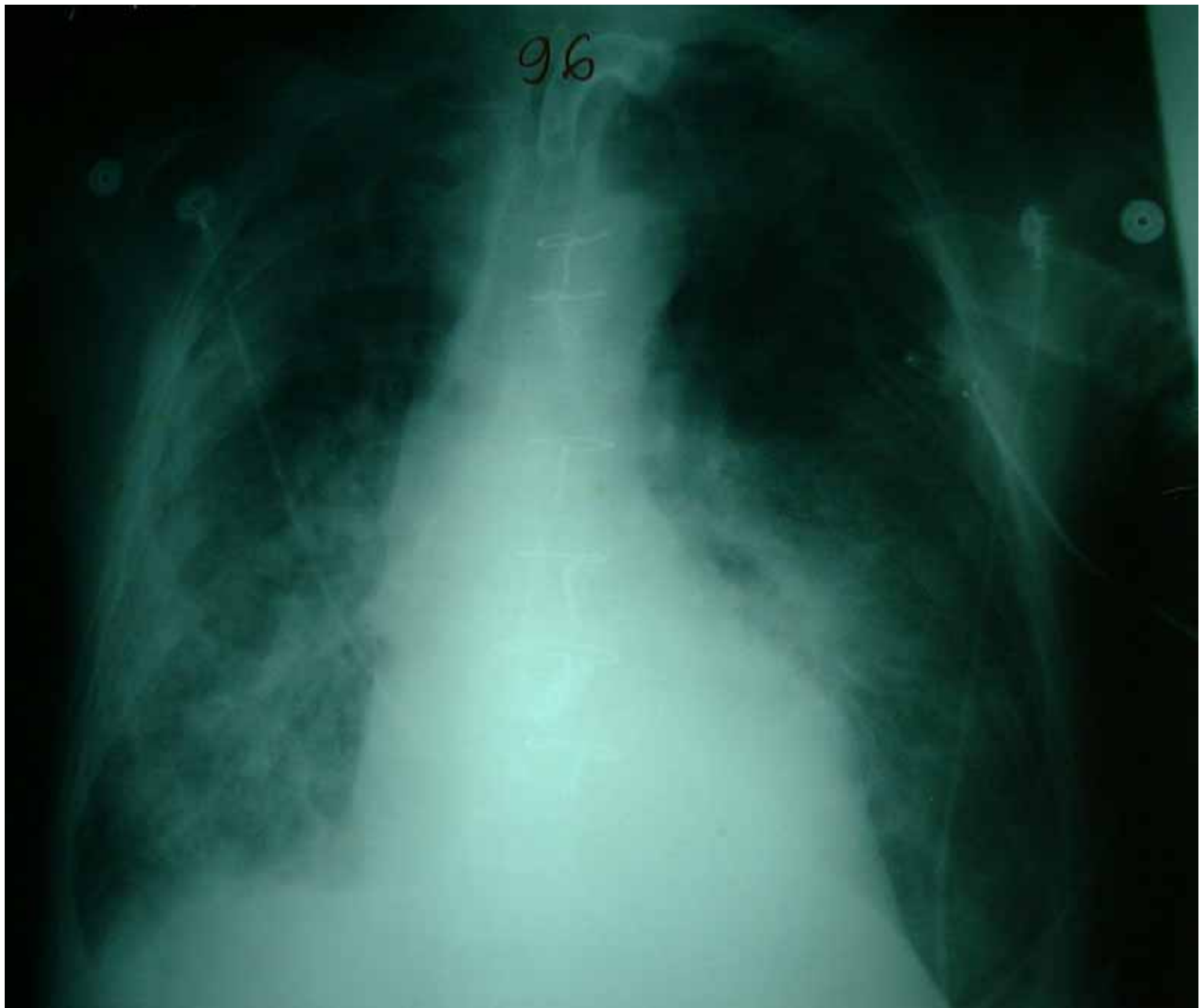


Après « pigtail »

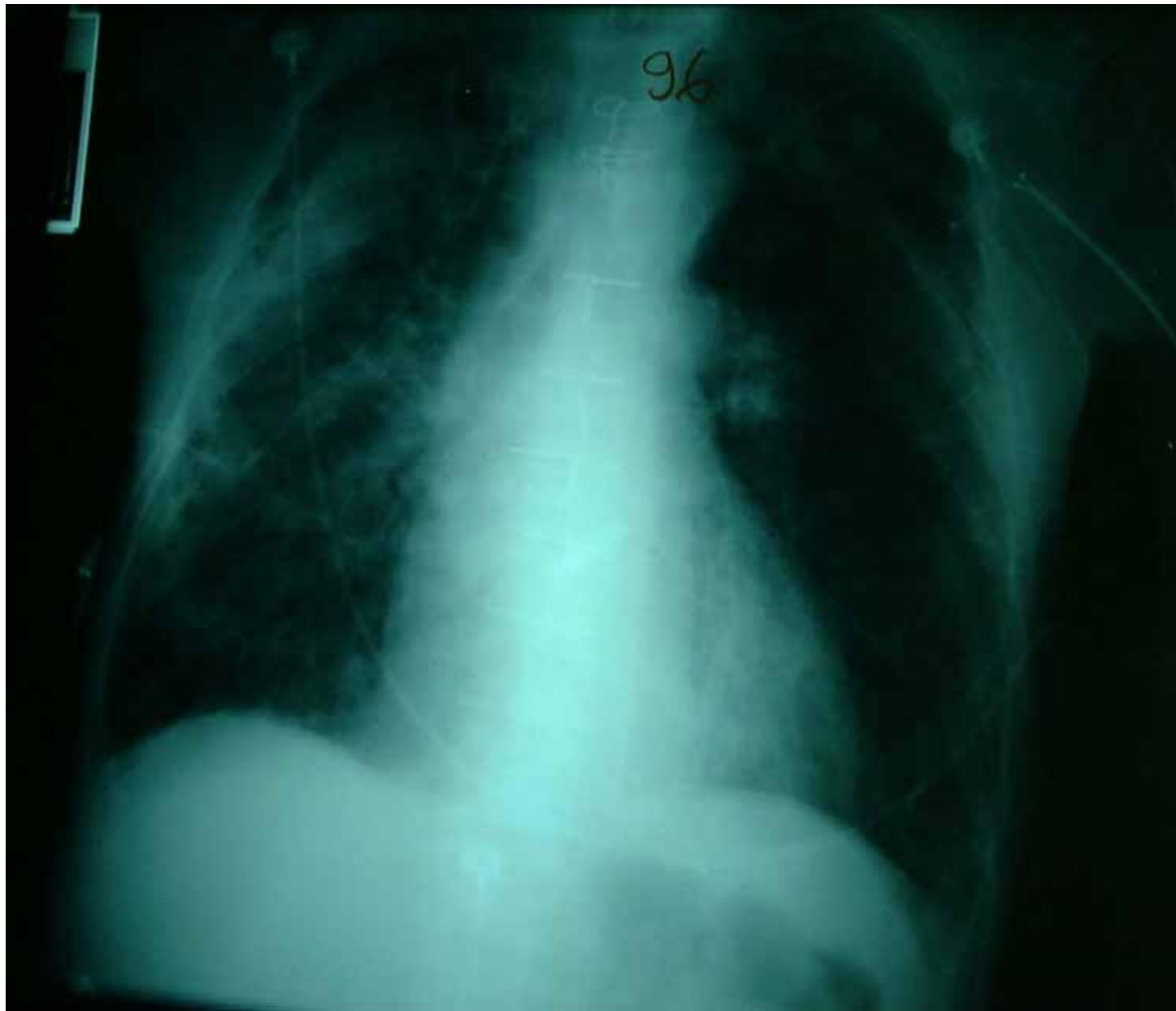


En salle d'opération



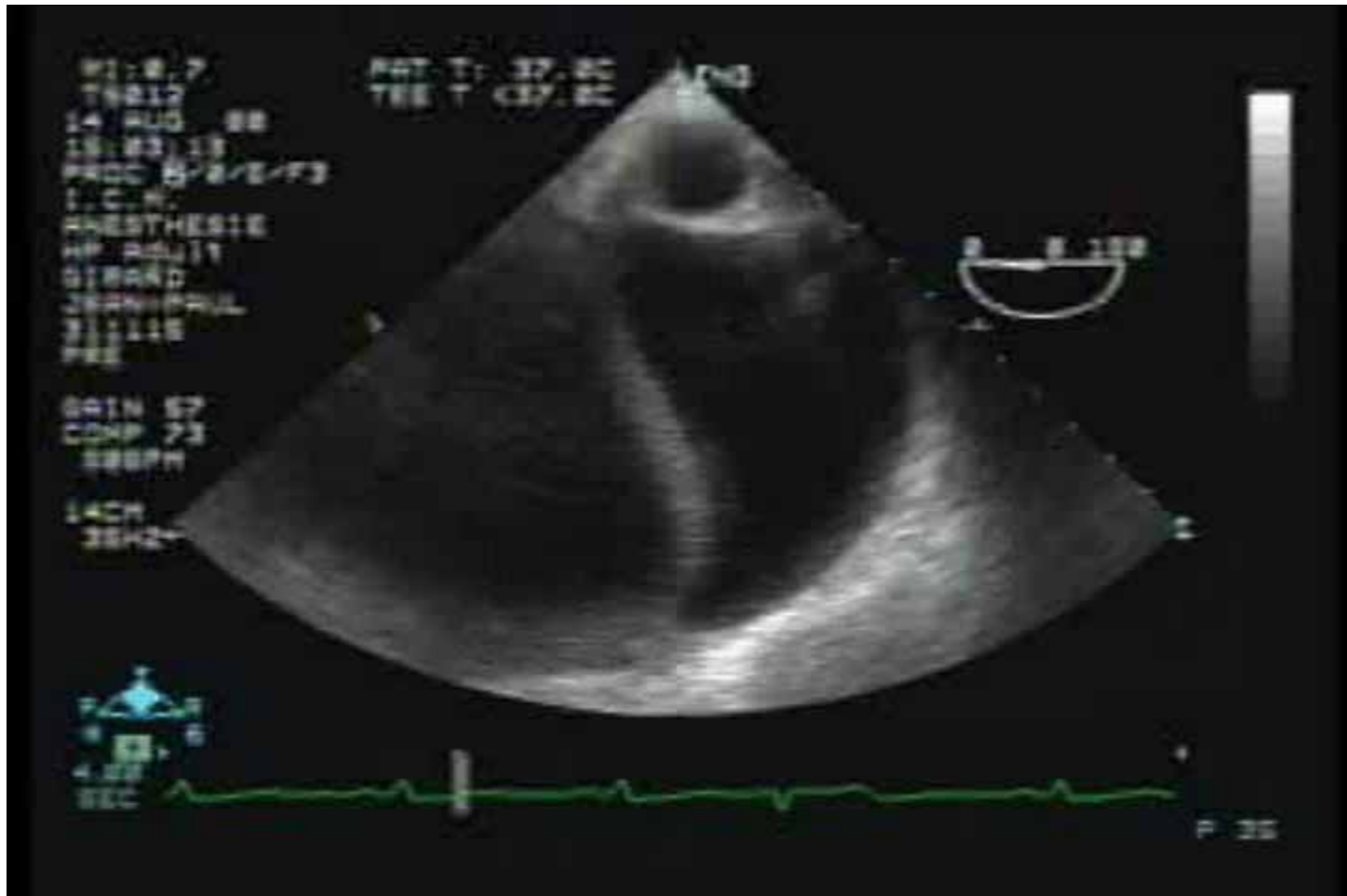


Homme de 71 ans post RVA compliquée par ?



Homme de 71 ans post pigtail = 2 litres D+G

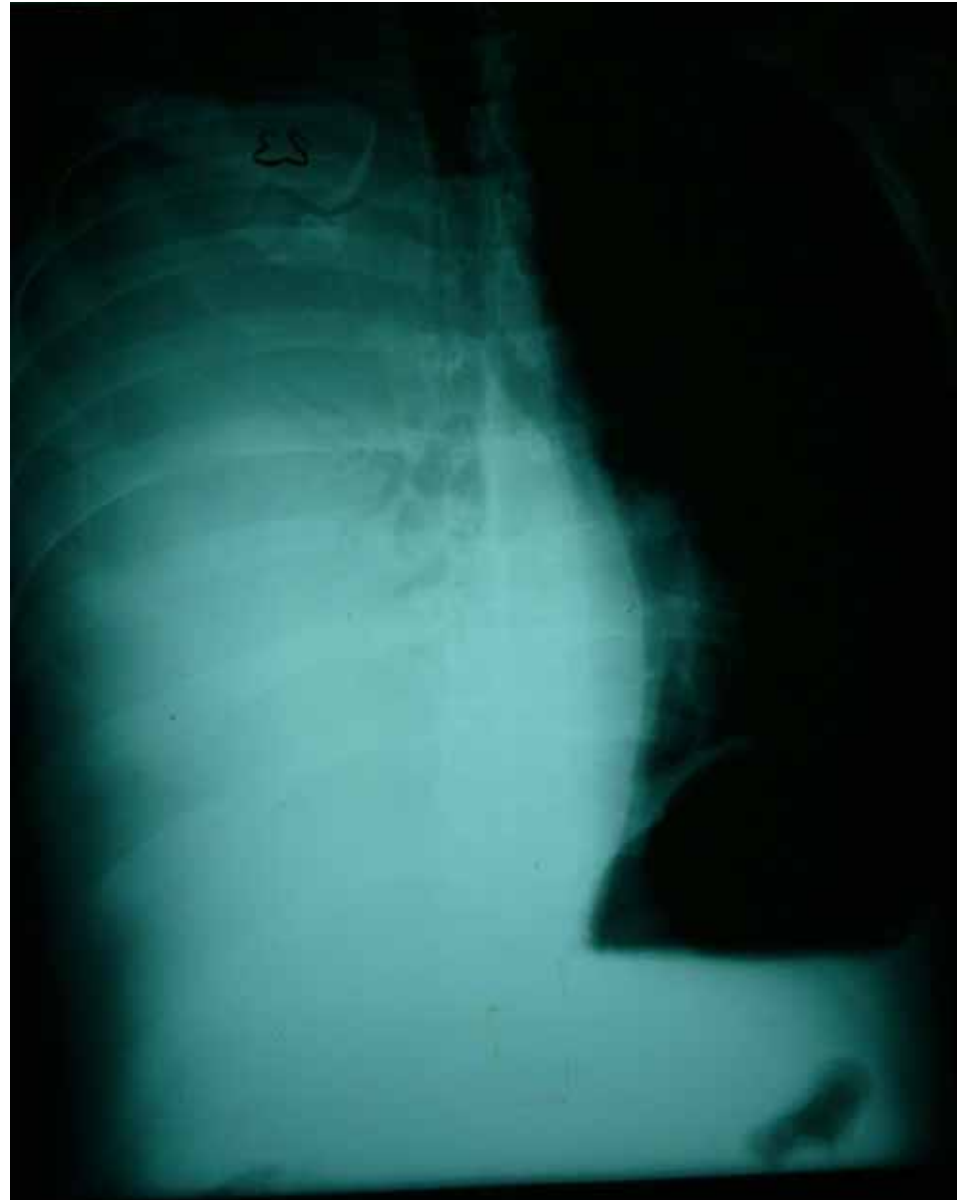Épanchements pleuraux en SOP

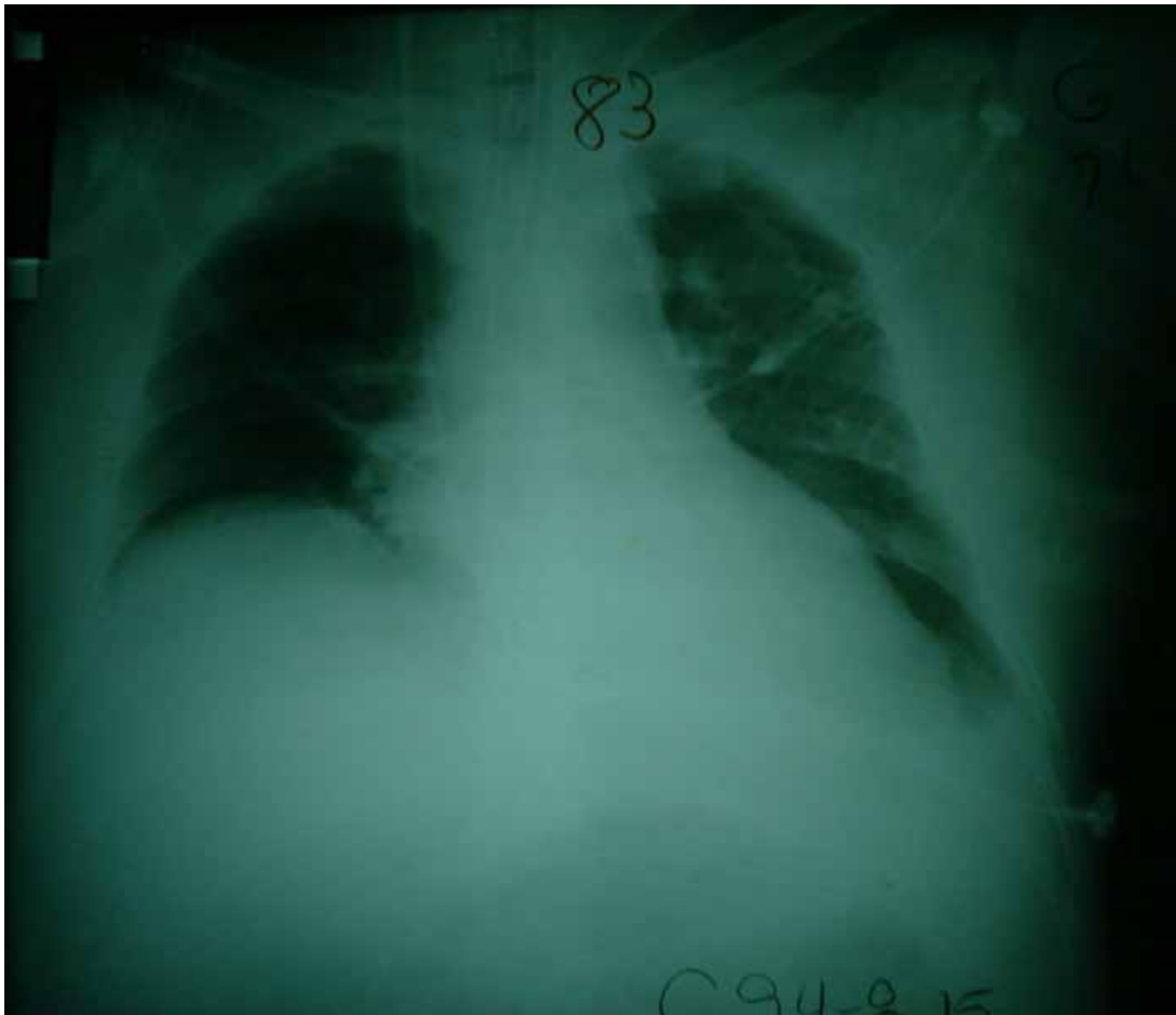


44 ans cirrhose

Épanchement d'origine extra-thoracique:

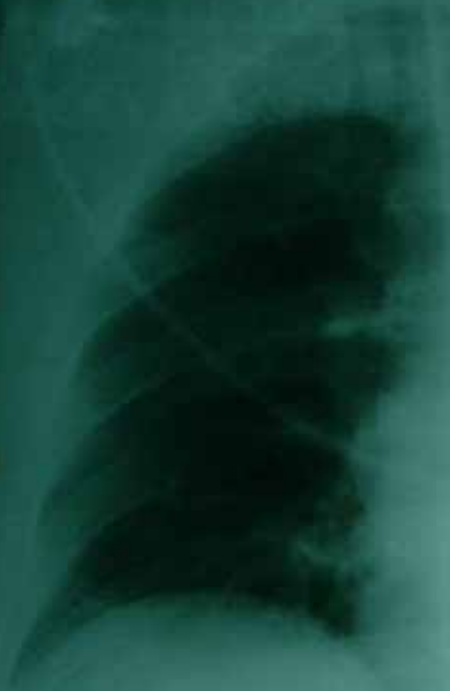- pancréatite
- abcès sous-phrénique
- post chirurgie abdominale
- syndrome de Meigs
- syndrome néphrotique
- surcharge liquidienne
- cirrhose





Greffe rénale défectueuse, catheter de dialyse installé

83

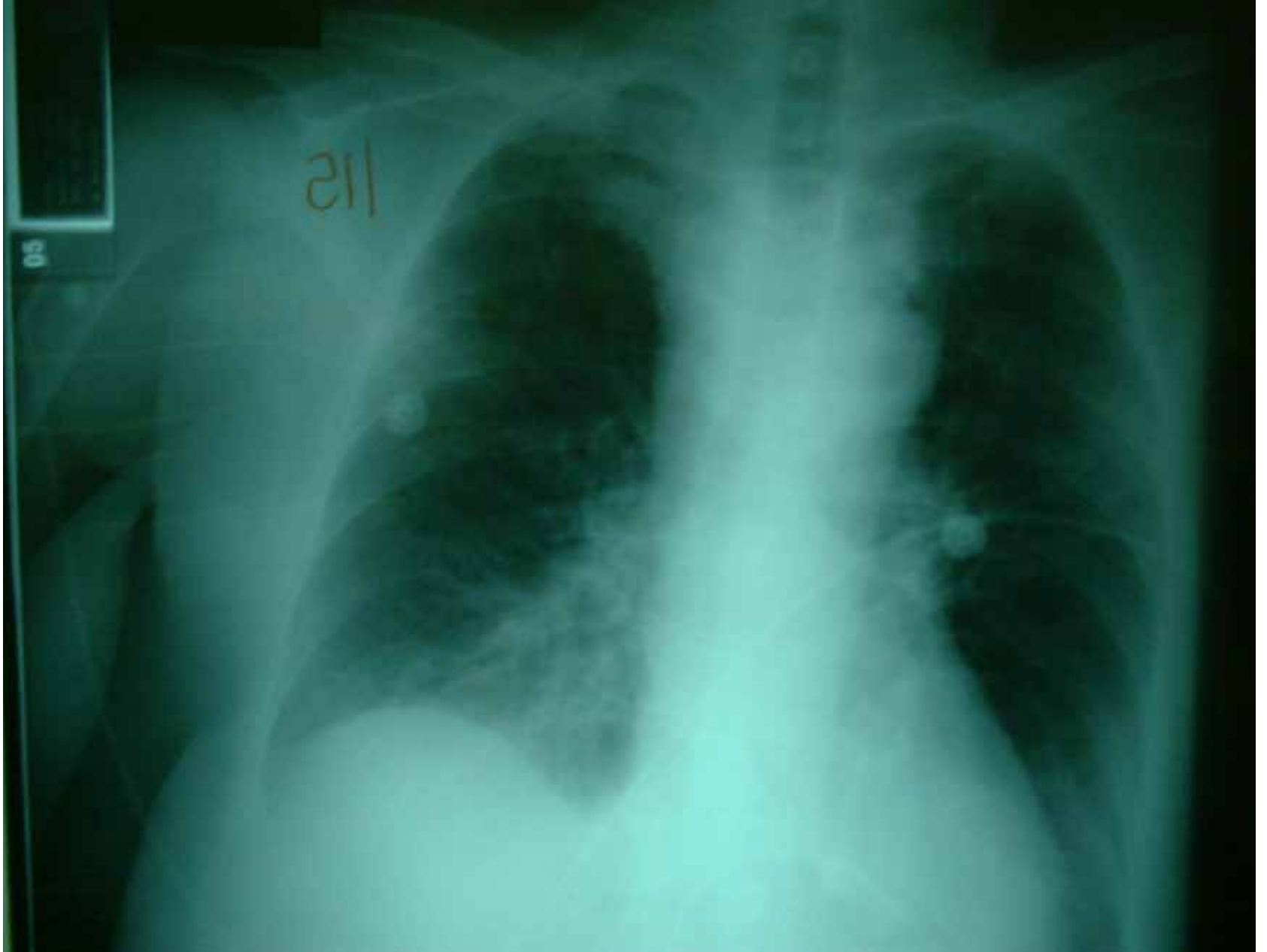

1991

83

2.15

Handwritten notes and markings on the chest X-ray, including a vertical line of numbers (1, 2, 3, 4, 5, 6, 7, 8, 9, 10, 11, 12, 13, 14, 15, 16, 17, 18, 19, 20, 21, 22, 23, 24, 25, 26, 27, 28, 29, 30, 31, 32, 33, 34, 35, 36, 37, 38, 39, 40, 41, 42, 43, 44, 45, 46, 47, 48, 49, 50, 51, 52, 53, 54, 55, 56, 57, 58, 59, 60, 61, 62, 63, 64, 65, 66, 67, 68, 69, 70, 71, 72, 73, 74, 75, 76, 77, 78, 79, 80, 81, 82, 83, 84, 85, 86, 87, 88, 89, 90, 91, 92, 93, 94, 95, 96, 97, 98, 99, 100) and a circled area on the right side.

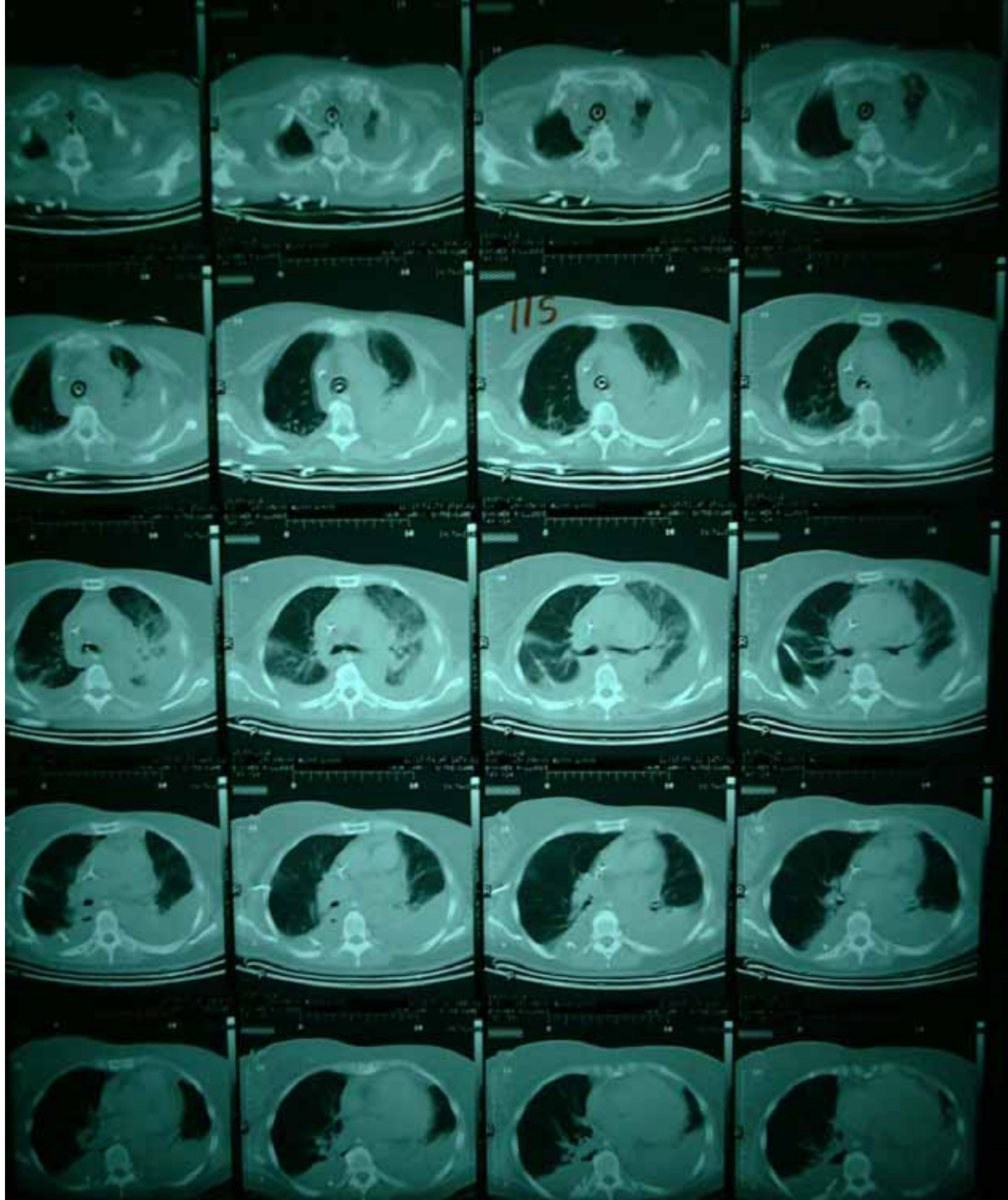


Besoin de voie centrale, RX de contrôle

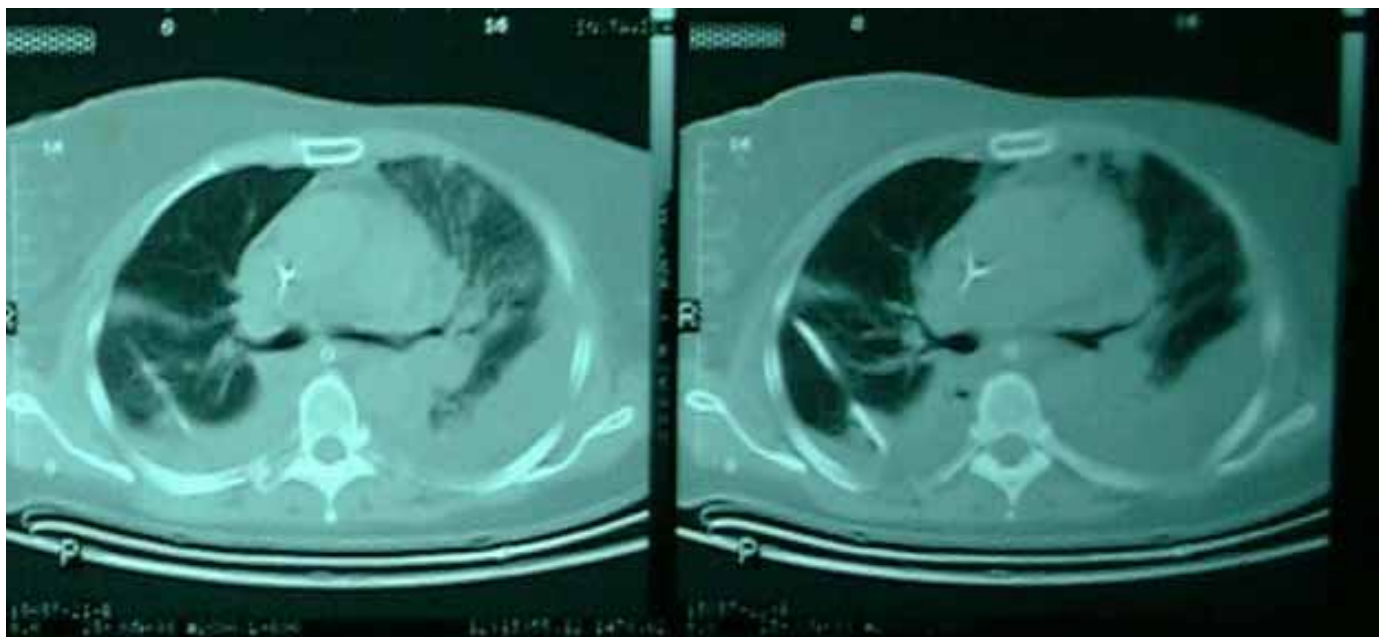
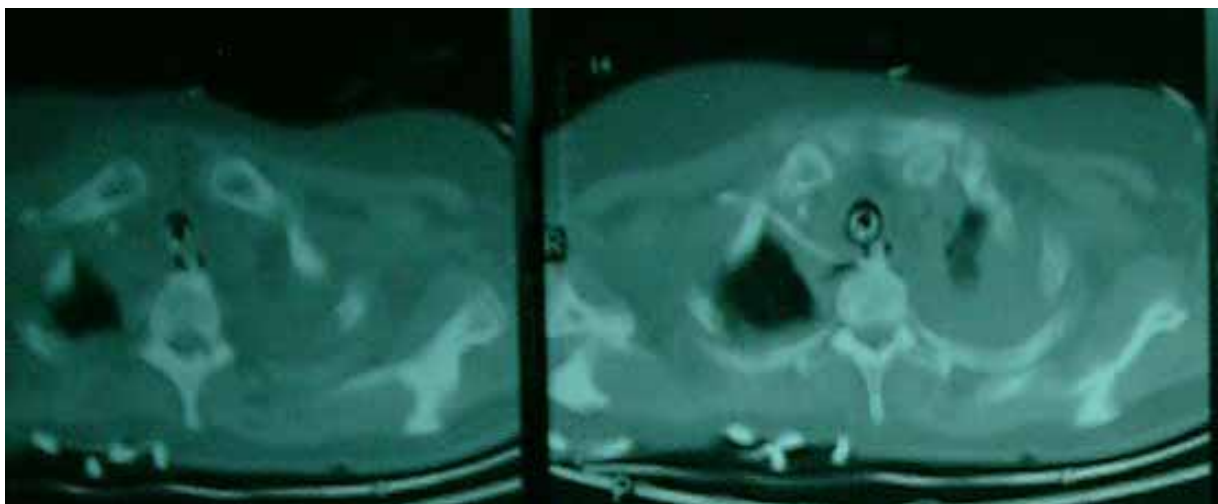
115

6-23-6-58





Complications X 2



Merci

Dr Lespérance,
Département de radiologie ICM



Denis Babin MSc Inh