



Perioperative right ventricular dysfunction

André Yvan Denault^{a,b}, Francois Haddad^c, Eric Jacobsohn^d, and Alain Deschamps^a

Purpose of review

To evaluate new information on the importance of right ventricular function, diagnosis and management in cardiac surgical patients.

Recent findings

There is growing evidence that right ventricular function is a key determinant in survival in cardiac surgery, particularly in patients with pulmonary hypertension. The diagnosis of this condition is helped by the use of specific hemodynamic parameters and echocardiography. In that regard, international consensus guidelines on the echocardiographic assessment of right ventricular function have been recently published. New monitoring modalities in cardiac surgery such as regional near-infrared spectroscopy can also assist management. Management of right ventricular failure will be influenced by the presence or absence of myocardial ischemia and left ventricular dysfunction. The differential diagnosis and management will be facilitated using a systematic approach.

Summary

The use of right ventricular pressure monitoring and the publications of guidelines for the echocardiographic assessment of right ventricular anatomy and function allow the early identification of right ventricular failure. The treatment success will be associated by optimization of the hemodynamic, echocardiographic and near-infrared spectroscopy parameters.

Keywords

echocardiography, hemodynamics, right ventricular failure, right ventricular function, transesophageal echocardiography

INTRODUCTION

Right ventricular dysfunction has been associated with increased mortality in both the cardiac surgical patients [1], the noncardiac setting and in the ICU [2,3]. Right ventricular failure can be present before, during or after cardiac surgery. It may also complicate any cardiac or noncardiac surgical procedures. In cardiac surgery, right ventricular dysfunction typically leads to difficult weaning from cardiopulmonary bypass (CPB) and increased postoperative mortality. In this article we will review the importance of right ventricular function and concentrate on its intraoperative and bedside evaluation using combined hemodynamic and echocardiographic criteria. Finally, a management strategy will be proposed based on the current literature and our experience with this condition.

IMPORTANCE OF PULMONARY HYPERTENSION AND RIGHT VENTRICULAR FUNCTION

It is well recognized that pulmonary hypertension represents a major risk factor for mortality in

patients undergoing cardiac surgery. In cardiac surgery, both the Parsonnet and euroSCORE model include pulmonary hypertension as an important contributor to risk stratification [4,5]. In noncardiac surgery, pulmonary hypertension has also been associated with worse outcome [3,6,7]. In 2009, an international expert consensus conference on pulmonary hypertension was published [8,9]. In these guidelines, the pathology, classification, natural history, screening, diagnosis and treatment were reviewed. There was, however, very little information on pulmonary hypertension in the cardiac

^aDepartment of Anesthesiology, Montreal Heart Institute, Université de Montréal, ^bDivision of Critical Care, Centre Hospitalier de l'Université de Montréal (CHUM), Montreal, Quebec, Canada, ^cDepartment of Cardiovascular, Stanford School of Medicine, Stanford, California, USA and ^dDepartment of Anesthesia and Perioperative Medicine, University of Manitoba, Winnipeg, Manitoba, Canada

Correspondence to André Y. Denault, Montreal Heart Institute, 5000 Belanger Street, Montreal, Quebec H1T 1C8, Canada. Tel: +1 514 376 3330; e-mail: andre.denault@umontreal.ca

Curr Opin Anesthesiol 2013, 26:000–000

DOI:10.1097/ACO.0b013e32835b8be2

KEY POINTS

- Right ventricular dysfunction is associated with a significant increase in mortality in cardiac surgery.
- Early recognition of right ventricular failure using combined echocardiographic and specific right ventricular hemodynamic variables is important.
- The treatment success will be associated by optimization of the hemodynamic, echocardiographic and tissue perfusion parameters.

and noncardiac surgical patient, except for its association with increased risk of mortality. This increased mortality associated with pulmonary hypertension is likely to be from right ventricular failure. Alternatively, pulmonary hypertension may be a marker of severity of left ventricular diastolic function, mitral regurgitation or pulmonary disease. To date, no consensus guidelines have been performed on the intraoperative management of right ventricular dysfunction.

The incremental importance of preoperative right ventricular dysfunction has not been systematically addressed in patients undergoing cardiac or noncardiac surgery. Similar to pulmonary hypertension, there are only retrospective studies and small prospective studies documenting the association between preoperative right ventricular dysfunction in cardiac surgery and increased postoperative complications and mortality [10,11]. The importance of postoperative right ventricular failure is well documented. Right ventricular failure occurring after cardiac surgery will be associated with difficult separation from CPB. The latter has been recently demonstrated to be an independent predictor of mortality in high-risk cardiac surgical patients [12²²]. Postoperative right ventricular failure after cardiac surgery or cardiac transplantation is associated with significant morbidity and mortality [13–16]. Furthermore, result from an international multicentered trial (NCT00458276) on intravenous tezosentan in prevention of right ventricular failure (presented at the Canadian Anesthesia annual meeting in 2010 in Toronto) showed a 37% mortality rate of those who developed right ventricular failure [17].

The mechanism through which right ventricular failure is associated with increased mortality could be explained by the double hit phenomenon [18²³]. With right ventricular failure, initially right atrial pressure (RAP) will increase. As RAP is a determinant of venous return, venous return and cardiac output will be reduced resulting in low perfusion

pressure. Secondly, the increased venous pressure transmitted through both the superior and inferior vena cava will increase the outflow pressure of vital organs such as the brain, kidney, gastrointestinal tract and the liver. Both conditions will result in tissue hypoperfusion. Another reason why right ventricular dysfunction could be associated with increased mortality could be related to a delayed diagnosis and suboptimal management. For instance, studies in critically ill patients have shown an association between excessive fluid balance, higher RAP and increased mortality [19²⁴,20]. Hypervolemia could worsen right ventricular function if unrecognized. In fact hypervolemia can overdistend the right ventricle (RV), increasing pericardial constraint, left ventricular inflow as well as effective stroke volume. However, no systematic evaluation of right ventricular function was performed in these studies.

RIGHT VENTRICULAR FUNCTION EVALUATION

The evaluation of right ventricular function is optimally performed using right heart catheterization and echocardiography. Right heart catheterization is the best method to diagnose pulmonary hypertension and in that regard, superior to echocardiography [21]. There are, however, no clear hemodynamic criteria that can be used in the definition or diagnosis of right ventricular failure. Classically hypotension, elevated RAP (usually >15 mmHg) and clear lungs have been proposed as key elements in the diagnosis of right ventricular failure. There are several limitations for this definition in the operating room setting. Firstly right ventricular failure can co-exist with left ventricular systolic or diastolic dysfunction; both can lead to hypotension or pulmonary edema. Secondly RAP can be elevated from raised intrathoracic or intra-abdominal pressure without any right ventricular dysfunction. Third, pulmonary hypertension is a risk factor for developing right ventricular failure. In a patient known to have pulmonary hypertension, the pulmonary artery pressure will initially be high. If the patient then develops right ventricular failure, the pulmonary artery pressure will pseudo-normalize as right ventricular function fails to generate adequate cardiac output. Therefore, if a pulmonary artery catheter is inserted in a patient with right ventricular failure, the pulmonary artery pressure may appear normal but RAP will be elevated. However, in this patient, both systemic and pulmonary artery pressure will be reduced to a similar degree. This explains why relative measurements of pulmonary hypertension, such as the

mean arterial to pulmonary ratio, better reflect the severity of pulmonary hypertension. In addition, they are better predictors of postoperative complications in cardiac surgery compared to the absolute values [22]. Finally, in right ventricular failure, measurement of cardiac output using thermodilution may be altered in the presence of tricuspid regurgitation [23–25]. This can make assessment of fluid or inotropic responsiveness difficult to document using a pulmonary artery catheter.

In patients with left ventricular assist device (LVAD), the Interagency Registry for Mechanically Assisted Circulatory Support (INTERMACS) proposes an inclusive definition of right ventricular failure. In the consensus document, right ventricular failure is defined as symptoms and signs of persistent right ventricular dysfunction (RAP >18 mmHg with a cardiac index <2.0 l/min/m²) [in the absence of elevated left atrial/pulmonary capillary wedge pressure (greater than 18 mmHg), tamponade, ventricular arrhythmias or pneumothorax]; any right ventricular failure requiring right ventricular assist device (RVAD) implantation or any right ventricular failure requiring inhaled nitric oxide or inotropic therapy for a duration of more than 1 week at any time after LVAD implantation [26]. For the perioperative period, a consensus definition of right ventricular failure has not yet been developed. In the following section, we present some potentially helpful criteria.

HEMODYNAMIC DIAGNOSIS OF RIGHT VENTRICULAR DYSFUNCTION

A new method that is used and promoted from the Montreal Heart Institute (MHI) is the use of continuous right ventricular pressure waveform monitoring. This method was described several years ago in the diagnosis of right ventricular ischemia [27,28], but not as a continuous monitoring modality. Our group has been using continuous right ventricular pressure waveform monitoring in order to detect changes in right ventricular function during cardiac surgery [22,29,30]. The diagnosis of right ventricular systolic dysfunction, diastolic dysfunction and right ventricular outflow tract obstruction (RVOTO) can be obtained instantaneously, in a dynamic fashion, using a pulmonary artery catheter, and continuously transducing the right ventricular port (Paceport, Edwards Lifescience, Irvine, CA) [31]. The normal right ventricular diastolic slope is typically horizontal due to the normal right ventricular compliance, which is much higher than the left ventricular compliance [29]. When right ventricular pressure is combined with pulmonary artery pressure monitoring, there should also be no significant

differences between the peak systolic pulmonary artery pressure and the systolic right ventricular pressure (Fig. 1). In right ventricular dysfunction, a progressive change from a horizontal to an oblique diastolic slope will be observed (Fig. 2). As right ventricular function deteriorates, it will change to a square root slope (Fig. 3) and then there will be equalization of the right ventricular to pulmonary artery diastolic pressure. With severe right ventricular systolic dysfunction delayed systolic upstroke (or right ventricular pulsus tardus) and reduction in right ventricular pulse pressure will be observed (Fig. 4). Another useful diagnosis that can be instantaneously made with right ventricular pressure waveform monitoring is RVOTO. This is readily seen whenever the right ventricular systolic pressure is 6 mmHg or more above the pulmonary artery systolic pressure (Fig. 5). The mechanism of RVOTO can be dynamic or mechanical. Dynamic RVOTO with gradients above 25 mmHg are observed in 4% of patients undergoing cardiac surgery, and they are associated with hemodynamic instability [31]. In this situation (which is analogous to dynamic left ventricular outflow tract obstruction associated with systolic anterior motion of the mitral valve), inotropic agents would be contra-indicated; however, volume and beta-blocking agents can be used if the RVOTO is nonmechanical. Mechanical RVOTO has been proposed as one of the mechanisms for hemodynamic instability that can occur in the prone position [32*]. We have described RVOTO in anterior pneumothorax [33], during sternal closure [33] and after lung transplantation [34,35]. Hemodynamic instability resulting from dynamic

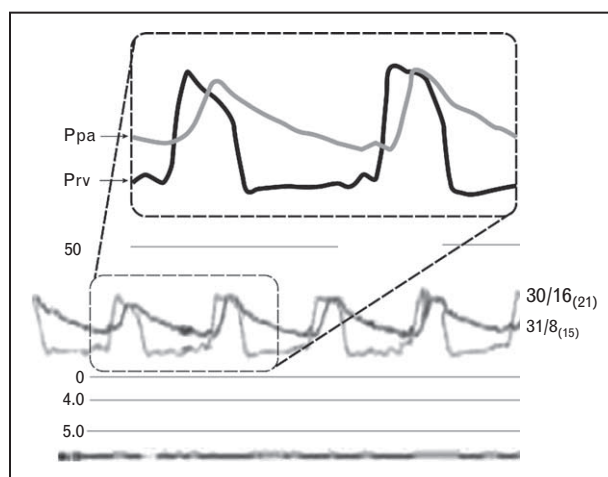


FIGURE 1. A normal right ventricular pressure (Prv) waveform has a horizontal diastolic slope. With a combined display, the pulmonary artery pressure (Ppa) and the systolic right ventricular pressure (Prv) should be similar (within 6 mmHg of each other).

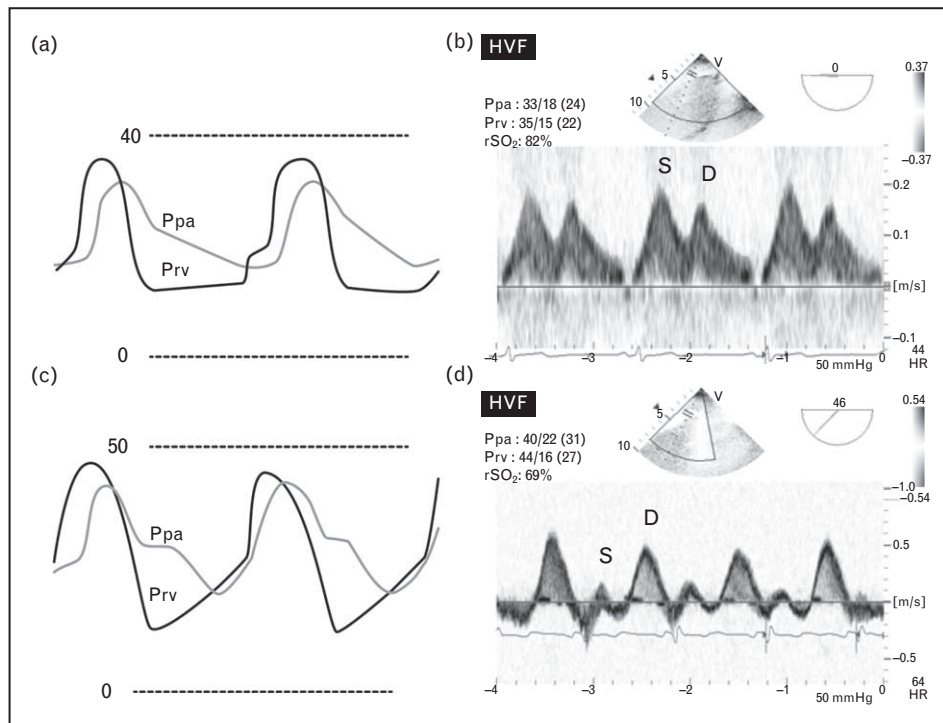


FIGURE 2. Zoomed right ventricular pressure (Prv) and pulmonary artery pressure (Ppa) with their corresponding Doppler hepatic venous flow (HVf) before (a, b) and after cardiopulmonary bypass (CPB). Note the change in the diastolic slope of the Prv waveform and the corresponding change in the systolic (S) to diastolic (D) ratio of the HVf. After CPB, the regional oxygen saturation of the brain (rSO₂) was lower, but still within normal limits ($60 \pm 5\%$) (Supplementary Digital Content 1a and 1b, <http://links.lww.com/COAN/A10>, <http://links.lww.com/COAN/A11>).

RVOTO is likely to be under-diagnosed in the perioperative period.

In the operating room, we simultaneously display both the pulmonary artery and the right ventricular pressure waveform throughout surgery. This technique may be the fastest and easiest way to diagnose hemodynamic instability resulting from right ventricular dysfunction or RVOTO. However, when right ventricular dysfunction is suspected, both cardiac and pulmonary echocardiography will be instrumental in determining the cause and consequences. For instance, right ventricular failure can result in pulmonary hypertension due to mitral regurgitation. Mitral regurgitation could be secondary to ischemia [36] or from left ventricular outflow tract obstruction [37]. Both conditions cause post-capillary pulmonary hypertension, but will have completely different medical or surgical management. Another example is hypoxia that can lead to pulmonary hypertension, right ventricular failure and increase in RAP. If RAP exceeds left atrial pressure, hypoxia can worsen through the opening of a patent foramen ovale with right to left shunt. This scenario could occur in potentially up to 20% of the population [38]. The cause of abnormal gas exchange such as pulmonary edema, atelectasis, pneumothorax and pleural effusion will also be

facilitated with bedside pulmonary ultrasound in up to 90% of patients [39,40[■]]. Lung ultrasound is discussed in more detail in another article of this issue.

ECHOCARDIOGRAPHIC DIAGNOSIS OF RIGHT VENTRICULAR DYSFUNCTION

Echocardiography will be useful to diagnose and elucidate the cause of right ventricular dysfunction and to diagnose any associated conditions such as valvular heart disease or pulmonary disease. It will also be useful in determining right ventricular dimensions and function, and will help the clinician in evaluating response to therapy. Specific conditions such as left ventricular systolic and diastolic dysfunction, valvular and congenital heart disease, left ventricular outflow tract obstruction, acute pulmonary embolism and other rare causes such as left atrial myxoma can be diagnosed using echocardiography. These conditions can be associated with pulmonary hypertension and consequently right ventricular failure. A detailed discussion of the role of echocardiography in the diagnosis of the cause of right ventricular failure is beyond the scope of this article. Their impact on right ventricular function will now be discussed.

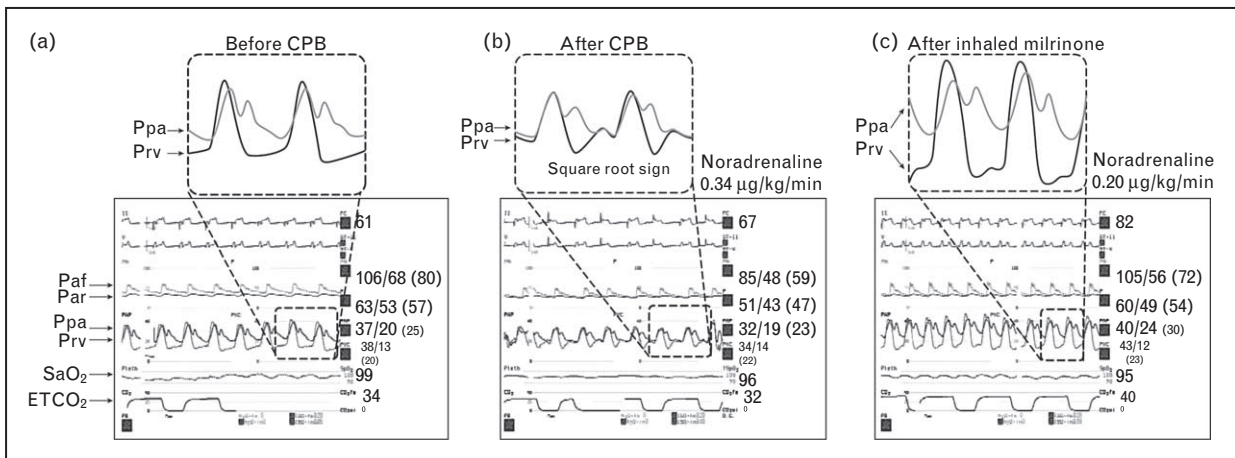


FIGURE 3. Baseline hemodynamic waveforms in a patient before cardiac surgery (a), after cardiopulmonary bypass (CPB) (b) and following the administration of inhaled milrinone (c). Note the relatively horizontal right ventricular pressure (Prv) waveform initially. After CPB, the Prv becomes abnormal and looks like a square root sign. Equalization of the Prv and the diastolic pulmonary artery pressure (Ppa) is also present. This was associated with hypotension and hemodynamic instability. Following administration of inhaled milrinone, the Prv waveform resumed a normal shape. This was associated with increased blood pressure, reduced noradrenaline requirement and increase in end-tidal carbon dioxide (ETCO₂) from 32 to 40 mmHg, suggesting improved cardiac output. Note also the significant difference between the arterial pressure measured in the femoral compared to the radial artery. Paf, femoral arterial pressure; Par, radial arterial pressure; SaO₂, oxygen saturation.

In 2010, international guidelines for the echocardiographic evaluation of the right heart in adults were published [41]. A total of 14 transthoracic views were described and a consensus was established in terms of quantitative assessment of right ventricular dimensions. In addition, formal criteria for the evaluation of right ventricular systolic and diastolic function were established. More detail on the echocardiographic assessment of right ventricular function can be found at the American Society of Echocardiography website (www.asecho.org).

Similar right ventricular views obtained using transesophageal echocardiography (TEE) were published in 2007 [11,29]. Both two-dimensional measurement and Doppler evaluation will be necessary to obtain a comprehensive evaluation of right ventricular function. Correlation between right ventricular pressure waveform, systolic and diastolic function using Doppler hepatic venous flow are commonly observed (Fig. 2). Newer techniques such as myocardial strain and 3D TEE will not be covered, but will become available in the near future [42].

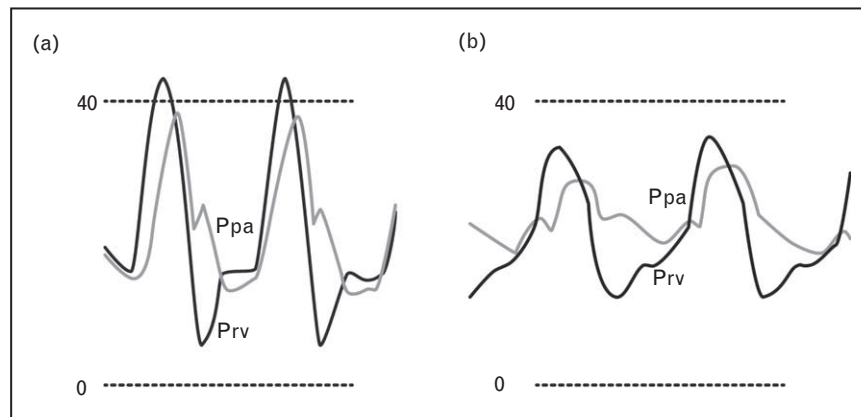


FIGURE 4. With severe right ventricular (RV) dysfunction, diastolic equalization of both RV pressure (Prv) and pulmonary artery pressure (Ppa) will be seen (a). As systolic RV dysfunction progresses (b), the systolic upstroke or the change of pressure over time will be slowed. This is the equivalent of pulsus tardus that can be typically seen in severe left ventricular failure or severe aortic stenosis.

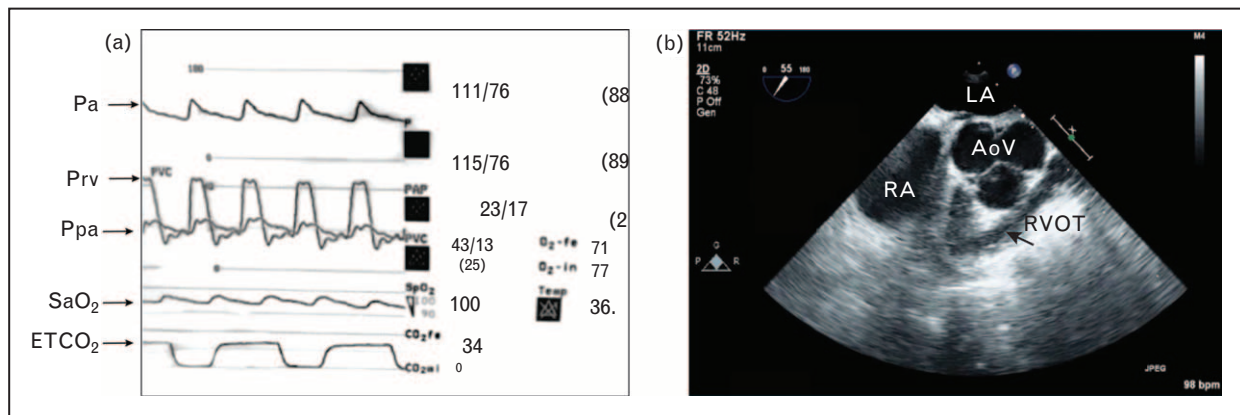


FIGURE 5. Right ventricular outflow tract (RVOT) obstruction at the beginning of cardiac surgery from mechanical compression during dissection of the right mammary artery (a). Note the 20 mmHg systolic difference between the right ventricular pressure ($Prv = 43/13$) and the pulmonary artery pressure ($Ppa = 23/17$). In the mid-esophageal inflow–outflow view, the abnormally reduced size of the RVOT is demonstrated. AoV, aortic valve; ETCO₂, end-tidal carbon dioxide; LA, left atrium; Pa, arterial pressure; RA, right atrium; SaO₂, oxygen saturation [Supplementary Digital Content 2a and 2b, <http://links.lww.com/COAN/A12>, <http://links.lww.com/COAN/A13>].

In summary, combining right ventricular pressure waveform monitoring and cardiopulmonary ultrasound monitoring allows rapid determination of the cause of right ventricular dysfunction, determination of right ventricular systolic and diastolic function, and exclusion or not of RVOTO. Pulmonary ultrasound will be useful in the presence of hypoxia. In addition, rapid evaluation of the therapeutic efficacy of agents used in right ventricular dysfunction can be used using these modalities (Fig. 3). There is, however, a limitation to both echocardiographic and hemodynamic monitoring. Some patients after cardiac surgery may develop abnormal right ventricular dysfunction based on echocardiographic criteria [43]. However, they still maintain adequate cardiac output and consequently adequate oxygen transport and tissue perfusion. How can we identify these patients who may not require any specific right ventricular failure treatment?

NEAR-INFRARED SPECTROSCOPY

Near-infrared spectroscopy (NIRS) is a noninvasive but nonspecific method to evaluate whether cardiac output is sufficient to maintain adequate oxygen transport in relation to oxygen demand. Simple tissue perfusion techniques such as mixed venous blood gas [44], arterio-venous carbon dioxide differences [45] and lactate measurements [46] are commonly used for that purpose. However, these measurements are intermittent and their results might represent a situation that happened several hours before. Regional cerebral oxygen saturation (rSO₂) monitoring using NIRS is a promising

technology that could help anesthesiologists in meeting these goals during cardiac or noncardiac surgery. The monitor gives a baseline numerical value of the rSO₂. Therefore, abnormal variation in NIRS can be addressed by the anesthesiologist using various interventions [35]. Studies have shown that intraoperative NIRS values correlate with postoperative outcome in cardiac [47] and in noncardiac surgery [48]. Interventions to correct brain saturation can be associated with improved outcome [49,50]. Finally in a recent prospective trial, baseline cerebral NIRS values obtained before cardiac surgery were superior to the euroSCORE in predicting survival in cardiac surgery [51].

Consequently, combining right ventricular pressure waveform, echocardiography and NIRS monitoring allows the anesthesiologist to differentiate the compensated normal or abnormal RV (normal NIRS values) (Fig. 2) to the uncompensated failing RV (reduced NIRS values) (Fig. 6). In the presence of normal right ventricular pressure waveform and reduced NIRS, the cause is likely to be noncardiogenic such as during acute hemorrhage for instance (Fig. 7). In the operating room, both end-tidal carbon dioxide and NIRS trends [52,53] are used to evaluate response to therapy. They are particularly useful in right ventricular failure compared to thermodilution, as they are not influenced by tricuspid regurgitation.

PERIOPERATIVE MANAGEMENT

A practical approach to hemodynamic instability following CPB or weaning failure is summarized in Fig. 8. Typically, hemodynamic instability will

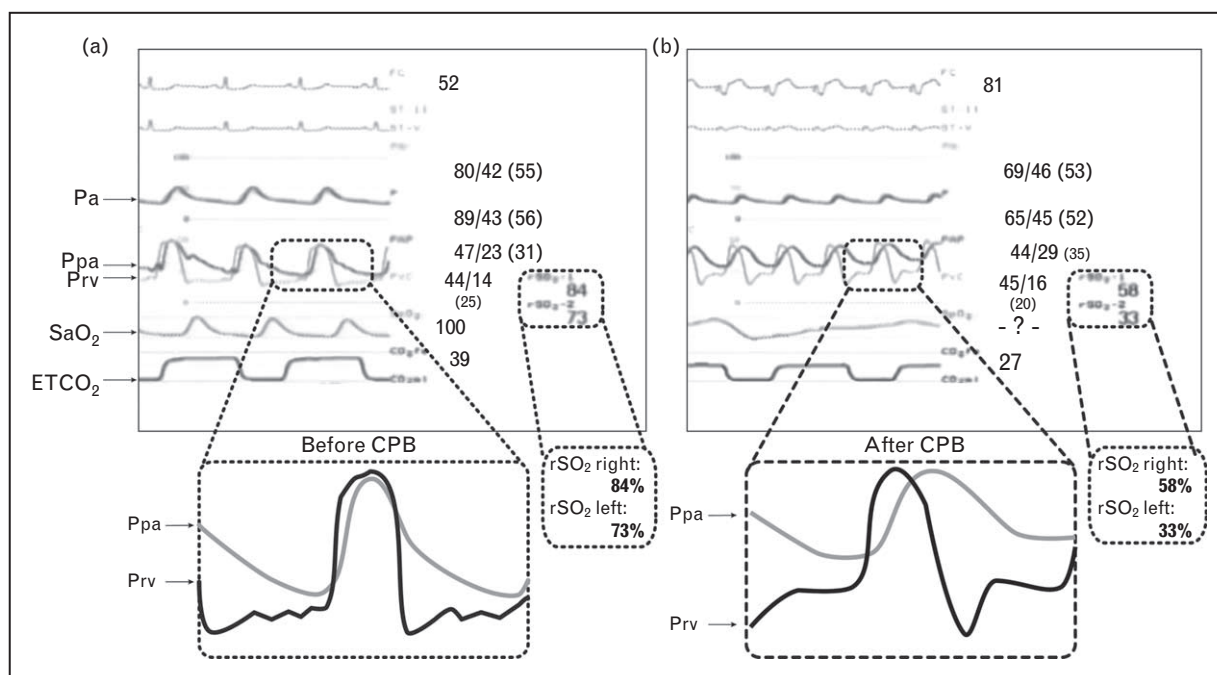


FIGURE 6. Hemodynamic waveforms combined with regional near-infrared spectroscopy (NIRS) values obtained before (a) and after cardiopulmonary bypass (CPB) (b). The upper NIRS value was obtained from the right lower extremity and the lower NIRS value is from the brain. Note that after CPB, both values were reduced significantly. This was associated with failure to wean from CPB and significant hemodynamic instability. The cause was a result of acute right ventricular (RV) failure, demonstrated on the RV pressure (Prv) waveform. Note the change of Prv from a normal shape before CPB to a square root sign, with diastolic equalization after CPB. Note also that the pulmonary artery pressure (Ppa) systolic values were lower after CPB and nondiagnostic of acute RV failure. The right atrial pressure was 16 mmHg compared to 14 mmHg before CPB. ETCO₂, end-tidal carbon dioxide; Pa, arterial pressure; rSO₂, regional oxygen saturation; Ppa, pulmonary artery pressure; SaO₂, oxygen saturation.

be associated with reduced cardiac output and low NIRS values indicating poor tissue perfusion (Fig. 6). In any hemodynamically unstable patient, it will also be important to obtain reliable arterial pressure as shown in Fig. 3 [54].

Secondly (step #2), it is important to recognize the presence of right ventricular dysfunction. Assessment of right ventricular function focuses on visual information (in the open chest condition), right ventricular pressure waveform analysis and echocardiographic assessment [32[■],41] of diastolic parameters, systolic performance indices and assessment of RVOTO [31]. The steps outlined below suggest a multimodality approach to the management of right ventricular dysfunction.

The next step (step #3) is to analyze right ventricular pressure waveform and to rule out RVOTO. The severity of hemodynamic instability correlates with a gradient above 25 mmHg [31]. The diagnosis can be confirmed with TEE. In this situation, if the mechanism is not from a mechanical compression, inotropic support should be reduced, volume administered and reduction in heart rate should

be considered. In step #4, right ventricular systolic and diastolic failure is confirmed. When right ventricular failure is present, particularly after cardiac transplantation, it is important to rule out any early surgical complication (step #5) such as compression of the pulmonary artery or obstruction at the pulmonary artery anastomosis [55[■]].

In all other cases priority will be to maintain hemodynamic stability and to avoid the vicious circle of hypotension and right ventricular ischemia. General measures should be implemented (step #6). These include heart rate and rhythm optimization, optimal fluid and blood management, avoiding reduced or excessive lung volume (in order to maintain a normal functional residual capacity) or drugs that could increase pulmonary artery pressure and maintain normal acid–base status [18[■]]. Shivering and hypothermia will also be important to prevent particularly in the postop period. The next important question will be to determine if an ischemic component is present and if there is evidence of left ventricular dysfunction. Medical or surgical reperfusion will be required if an ischemic condition

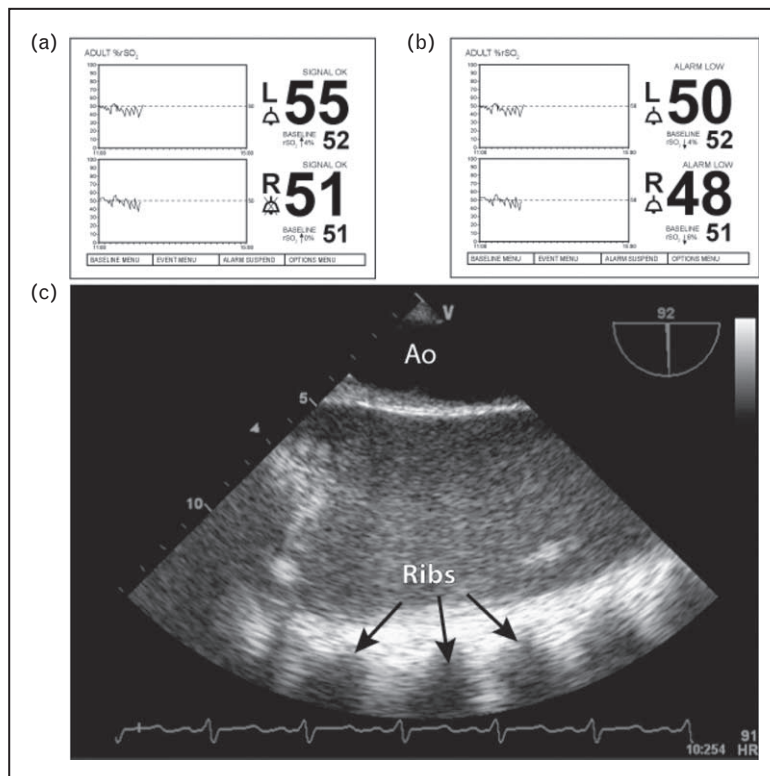


FIGURE 7. Postcardiopulmonary bypass (CPB) reduction in cerebral near-infrared spectroscopy (NIRS) in a 54-year-old woman undergoing coronary revascularization and resection of an interatrial mass (a, b). The right ventricular pressure waveform was normal at the time (not shown). Significant reduction in hemoglobin from 14.7 to 9.2 g/l was noted. Lung ultrasound examination revealed the presence of a massive hemothorax in the left pleural space. This was most likely from occult bleeding of the left internal mammary artery (c). Ao, aorta (Supplementary Digital Content 3, <http://links.lww.com/COAN/A14>).

is suspected (step #7). In the cardiac operating theater, communication within the cardiac team will play a key role. This question will need to be answered rapidly. In some instances, return on CPB will be indicated particularly if persistent reduced NIRS values are present. This will allow planning the next strategy. In some severe cases mechanical devices might be considered as a bridge to recovery or as a bridge to transplantation [56[□]].

In some case of right ventricular failure, there will be no evidence of ischemia and left ventricular failure (step #8). This may occur in severe pulmonary reperfusion syndrome [30,57], in patients who have reduced right ventricular reserve and during carbon dioxide embolism [58]. In conditions with elevated pulmonary vascular resistance, right ventricular afterload reduction can lead to dramatic improvement [58]. Although nitric oxide can be used, many centers have been using mostly inhaled prostacyclin [59,60] and inhaled milrinone alone or in combination because of the reduced cost, rapid onset of action and simplicity of administration [61,62]. Sublingual sildenafil has also been suggested as an alternative [63,64]. Experience with

this form of administration in the operating room has not been reported yet. More details on the various drugs and their mechanisms of action can be found in a review by Gordon *et al.* [65]. In high-risk patients, we administer inhaled agents before CPB in order to possibly prevent or attenuate the reperfusion injury [62]. An ongoing multicentered randomized controlled trial on inhaled milrinone in high-risk cardiac surgery (NCT00819377) will be completed in 2013 and will provide more insight into the effectiveness of this approach. Increasing right ventricular contractility will also be useful in right ventricular failure as long as there is no left ventricular outflow tract obstruction. In that situation, phosphodiesterase inhibitor or beta agonist alone or in combination with vasopressin or α -agonist, if required, can be used to maintain right coronary perfusion pressure.

Finally (step #9) it is important to evaluate other conditions that can be associated with reduced oxygen transport, with or without right ventricular failure. These include conditions associated with reduced cardiac output or venous return such as low mean systemic pressure (distributive or hemorrhagic shock) (Fig. 8), increased RAP (cardiogenic

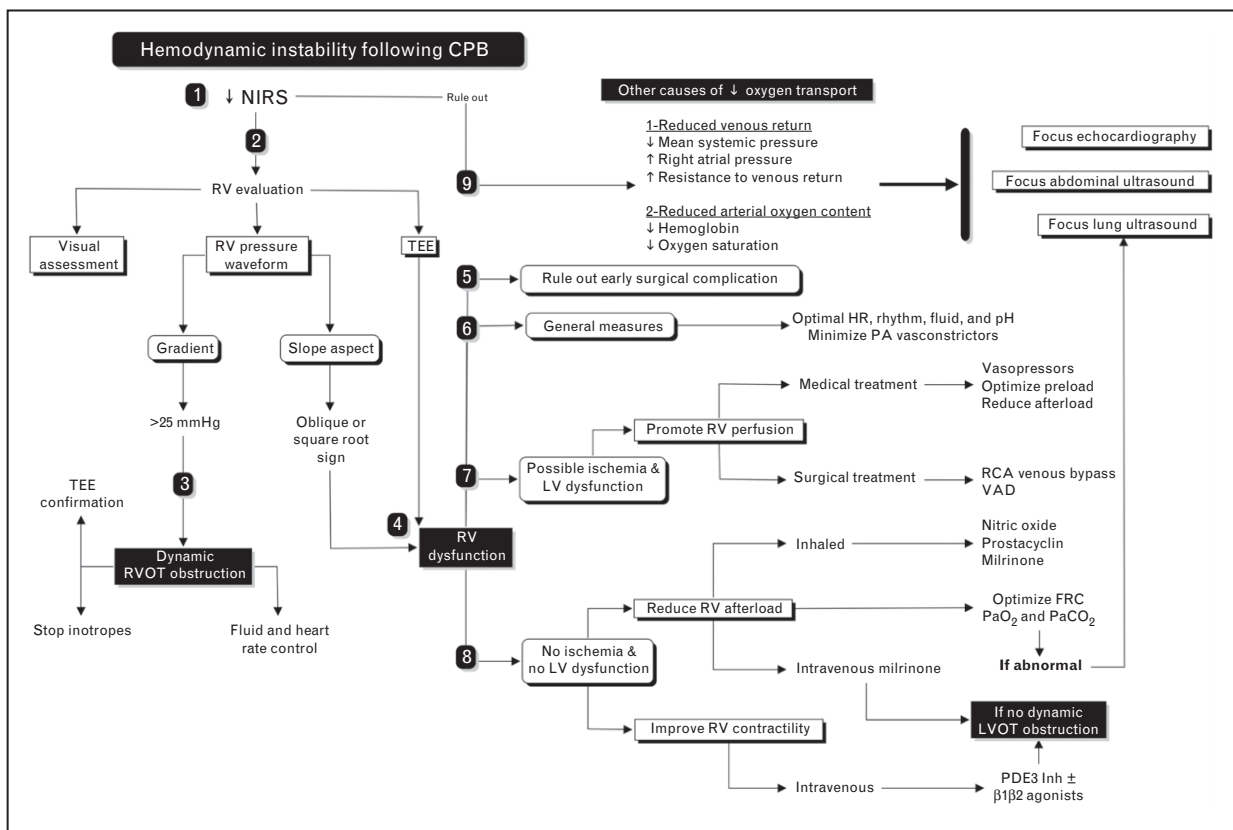


FIGURE 8. Bedside approach to acute right ventricular (RV) dysfunction in cardiac surgery. See text for details. CPB, cardiopulmonary bypass; FRC, functional residual capacity; HR, heart rate; LV, left ventricle; LVOT, left ventricular outflow tract; NIRS, near-infrared spectroscopy; PDE3 inh, phosphodiesterase inhibitors type 3; RCA, right coronary artery; RVOT, right ventricular outflow tract; TEE, transesophageal echocardiography; VAD, ventricular assist devices.

shock for instance acute mitral regurgitation from prosthetic dysfunction) and increased resistance to venous return (obstructive shock). We have observed the latter to occur at sternal closure due to mediastinal tamponade, during iatrogenic inferior vena cava occlusion and occult abdominal bleeding causing abdominal compartment syndrome [33,34]. Those conditions, associated with reduced arterial oxygen content, include acute anemias (Fig. 8), functional anemias (meth carboxy-hemoglobinemia) or reduction in oxygen saturation. The latter, in addition to hypercapnia, will increase pulmonary artery pressures and RAP. In this last step, cardiac, pulmonary and abdominal ultrasound can be used to help in the diagnosis and management.

CONCLUSION

The occurrence of right ventricular failure is a major complication associated with significant morbidity and mortality. A thorough understanding of the complex physiology of the RV is required to successfully diagnose and manage this condition. Patients

with pulmonary hypertension are predisposed to develop right ventricular failure. However, as right ventricular failure progresses, pulmonary artery pressures will pseudo-normalize but RAP will remain elevated. Thermodilution cardiac output is often misleading. Conventional monitoring with a pulmonary artery catheter alone may therefore be limited in making the diagnosis. Bedside echocardiography and right ventricular pressure waveform monitoring can be very useful in making the diagnosis of right ventricular failure. The importance of oxygen transport can be evaluated through the use of NIRS. Response to therapy will be associated with normalization of all these parameters.

Acknowledgements

The authors would like to thank Antoinette Paolitto and Denis Babin for their help with the manuscript.

Conflicts of interest

The work was supported by the Fonds de Recherche Québec en Santé. Dr Denault has been invited by Covidien as a speaker.

REFERENCES AND RECOMMENDED READING

Papers of particular interest, published within the annual period of review, have been highlighted as:

- of special interest
- of outstanding interest

Additional references related to this topic can also be found in the Current World Literature section in this issue (pp. 000–000).

1. Haddad F, Doyle R, Murphy DJ, *et al.* Right ventricular function in cardiovascular disease, part II: pathophysiology, clinical importance, and management of right ventricular failure. *Circulation* 2008; 117:1717–1731.
2. Ribeiro A, Lindmarker P, Juhlin-Dannfelt A, *et al.* Echocardiography Doppler in pulmonary embolism: right ventricular dysfunction as a predictor of mortality rate. *Am Heart J* 1997; 134:479–487.
3. Ramakrishna G, Sprung J, Ravi BS, *et al.* Impact of pulmonary hypertension on the outcomes of noncardiac surgery: predictors of perioperative morbidity and mortality. *J Am Coll Cardiol* 2005; 45:1691–1699.
4. Nashef SA, Roques F, Michel P, *et al.* European system for cardiac operative risk evaluation (EuroSCORE). *Eur J Cardiothorac Surg* 1999; 16:9–13.
5. Bernstein AD, Parsonnet V. Bedside estimation of risk as an aid for decision-making in cardiac surgery. *Ann Thorac Surg* 2000; 69:823–828.
6. Yeo TC, Dujardin KS, Tei C, *et al.* Value of a Doppler-derived index combining systolic and diastolic time intervals in predicting outcome in primary pulmonary hypertension. *Am J Cardiol* 1998; 81:1157–1161.
7. Price LC, Montani D, Jais X, *et al.* Noncardiothoracic nonobstetric surgery in mild-to-moderate pulmonary hypertension. *Eur Respir J* 2010; 35:1294–1302.
8. McLaughlin VV, Archer SL, Badesch DB, *et al.* ACCF/AHA 2009 expert consensus document on pulmonary hypertension: a report of the American College of Cardiology Foundation Task Force on Expert Consensus Documents and the American Heart Association developed in collaboration with the American College of Chest Physicians; American Thoracic Society, Inc.; and the Pulmonary Hypertension Association. *J Am Coll Cardiol* 2009; 53:1573–1619.
9. Simonneau G, Robbins IM, Beghetti M, *et al.* Updated clinical classification of pulmonary hypertension. *J Am Coll Cardiol* 2009; 54 (1 Suppl):S43–S54.
10. Maslow AD, Regan MM, Panzica P, *et al.* Precardiopulmonary bypass right ventricular function is associated with poor outcome after coronary artery bypass grafting in patients with severe left ventricular systolic dysfunction. *Anesth Analg* 2002; 95:1507–1518.
11. Haddad F, Couture P, Tousignant C, *et al.* The right ventricle in cardiac surgery, a perioperative perspective: II. Pathophysiology, clinical importance, and management. *Anesth Analg* 2009; 108:422–433.
12. Denault AY, Tardif JC, Mazer CD, *et al.* Difficult and complex separation from cardiopulmonary bypass in high-risk cardiac surgical patients: a multicenter study. *J Cardiothorac Vasc Anesth* 2012; 26:608–616.

Using the Montreal Heart Institute (MHI) database and a multicenter Canadian study comparing antifibrinolytics in high risk cardiac surgical patients (The BART study), these authors demonstrated that difficult separation from CPB is an independent predictor of postoperative morbidity and mortality. In the BART study (*NEJM* 2008), right-ventricular failure was responsible of 21% of those patients who died from a cardiogenic cause. However, it was not systematically recorded or documented using the most recent guidelines.

13. Reichert CL, Visser CA, van den Brink RB, *et al.* Prognostic value of biventricular function in hypotensive patients after cardiac surgery as assessed by transesophageal echocardiography. *J Cardiothorac Vasc Anesth* 1992; 6:429–432.
14. Davila-Roman VG, Waggoner AD, Hopkins WE, *et al.* Right ventricular dysfunction in low output syndrome after cardiac operations: assessment by transesophageal echocardiography. *Ann Thorac Surg* 1995; 60:1081–1086.
15. Kaul TK, Fields BL. Postoperative acute refractory right ventricular failure: incidence, pathogenesis, management and prognosis. *Cardiovasc Surg* 2000; 8:1–9.
16. Haddad F, Fisher P, Pham M, *et al.* Right ventricular dysfunction predicts poor outcome following hemodynamically compromising rejection. *J Heart Lung Transplant* 2009; 28:312–319.
17. Denault AY, Pearl RG, Michler RE, *et al.* Multicentered trial of Tezosentan in cardiac surgery. *Can J Anesth* 2010; S227.
18. Strumpher J, Jacobsohn E. Pulmonary hypertension and right ventricular dysfunction: physiology and perioperative management. *J Cardiothorac Vasc Anesth* 2011; 25:687–704.

Excellent review on pulmonary hypertension and its impact on right ventricular function. A comprehensive review of numerous possible therapies is presented.

19. Boyd JH, Forbes J, Nakada TA, *et al.* Fluid resuscitation in septic shock: a positive fluid balance and elevated central venous pressure are associated with increased mortality. *Crit Care Med* 2011; 39:259–265.

The VASST trial which compared the use of norepinephrine and vasopressin in 778 patients with septic shock (*NEJM* 2008). In this study the authors analyzed retrospectively fluid balance in those patients. They observed a direct correlation between fluid balance, central venous pressure and mortality. However, elevated central venous could be an indirect sign of right ventricular dysfunction which was not analyzed in this study.

20. Arian AA, Zappitelli M, Goldstein SL, *et al.* Fluid overload is associated with impaired oxygenation and morbidity in critically ill children. *Pediatr Crit Care Med* 2012; 13:253–258.
21. Fisher MR, Forfia PR, Chamera E, *et al.* Accuracy of Doppler echocardiography in the hemodynamic assessment of pulmonary hypertension. *Am J Respir Crit Care Med* 2009; 179:615–621.
22. Robitaille A, Denault AY, Couture P, *et al.* Importance of relative pulmonary hypertension in cardiac surgery: the mean systemic-to-pulmonary artery pressure ratio. *J Cardiothorac Vasc Anesth* 2006; 20:331–339.
23. Nishikawa T, Dohi S. Errors in the measurement of cardiac output by thermodilution. *Can J Anaesth* 1993; 40:142–153.
24. Heerd PM, Blessios GA, Beach ML, *et al.* Flow dependency of error in thermodilution measurement of cardiac output during acute tricuspid regurgitation. *J Cardiothorac Vasc Anesth* 2001; 15:183–187.
25. Balik M, Pachel J, Hendl J. Effect of the degree of tricuspid regurgitation on cardiac output measurements by thermodilution. *Intensive Care Med* 2002; 28:1117–1121.
26. Kavarana MN, Pessin-Minsley MS, Urtecho J, *et al.* Right ventricular dysfunction and organ failure in left ventricular assist device recipients: a continuing problem. *Ann Thorac Surg* 2002; 73:745–750.
27. Kinch JW, Ryan TJ. Right ventricular infarction. *N Engl J Med* 1994; 330:1211–1217.
28. Goldstein JA, Barzilai B, Rosamond TL, *et al.* Determinants of hemodynamic compromise with severe right ventricular infarction. *Circulation* 1990; 82:359–368.
29. Haddad F, Couture P, Tousignant C, *et al.* The right ventricle in cardiac surgery, a perioperative perspective: I. Anatomy, physiology, and assessment. *Anesth Analg* 2009; 108:407–421.
30. Denault A, Deschamps A, Tardif JC, *et al.* Pulmonary hypertension in cardiac surgery. *Curr Cardiol Rev* 2010; 6:1–14.
31. Denault AY, Chaput M, Couture P, *et al.* Dynamic right ventricular outflow tract obstruction in cardiac surgery. *J Thorac Cardiovasc Surg* 2006; 132:43–49.
32. Neira VM, Gardin L, Ryan G, *et al.* A transesophageal echocardiography examination clarifies the cause of cardiovascular collapse during scoliosis surgery in a child. *Can J Anesth* 2011; 58:451–455.

This article describes one mechanism of hemodynamic instability during prone position which is right ventricular outflow tract obstruction. The other mechanism being abdominal compartment syndrome. Both conditions could contribute to hypotension particularly in patients who may have predispositions or risk factors for both causes.

33. Denault AY. Difficult separation from cardiopulmonary bypass: importance, mechanism and prevention (PhD Thesis: www.mediaenligne.umontreal.ca/medclin/anesth/denault_phd.wmv) Université de Montréal; 2010.
34. Denault AY, Couture P, Vegas, *et al.* Transesophageal Echocardiography Multimedia Manual, Second Edition: A Perioperative Transdisciplinary Approach. New York: Informa Healthcare; 2010.
35. Denault AY, Ferraro P, Couture P, *et al.* Transesophageal echocardiography monitoring in the intensive care department: the management of hemodynamic instability secondary to thoracic tamponade after single lung transplantation. *J Am Soc Echocardiogr* 2003; 16:688–692.
36. Silbiger JJ. Mechanistic insights into ischemic mitral regurgitation: echocardiographic and surgical implications. *J Am Soc Echocardiogr* 2011; 24:707–719.
37. Rochon AG, L'Allier PL, Denault AY. Always consider left ventricular outflow tract obstruction in hemodynamically unstable patients. *Can J Anesth* 2009; 56:962–968.
38. Sukernik MR, Mets B, Bennett-Guerrero E. Patent foramen ovale and its significance in the perioperative period. *Anesth Analg* 2001; 93:1137–1146.
39. Lichtenstein DA, Meziere GA. Relevance of lung ultrasound in the diagnosis of acute respiratory failure: the BLUE protocol. *Chest* 2008; 134:117–125.
40. Volpicelli G, Elbarbary M, Blaivas M, *et al.* International evidence-based recommendations for point-of-care lung ultrasound. *Intensive Care Med* 2012; 38:577–591.

In 2009, the American College of Chest Physician in collaboration with the Société de Réanimation de Langue Française published a statement on competence in critical care. This consensus conference by Volpicelli was based on a panel of 28 experts. The importance of bedside lung ultrasound is recognized and its use is raising interest worldwide.

41. Rudski LG, Lai WW, Afilalo J, *et al.* Guidelines for the Echocardiographic Assessment of the Right Heart in Adults: A Report from the American Society of Echocardiography Endorsed by the European Association of Echocardiography, a registered branch of the European Society of Cardiology, and the Canadian Society of Echocardiography. *J Am Soc Echocardiogr* 2010; 23:685–713.
42. Karhausen J, Dudaryk R, Phillips-Bute B, *et al.* Three-dimensional transesophageal echocardiography for perioperative right ventricular assessment. *Ann Thorac Surg* 2012; 94:468–474.

The right-ventricular shape is much more complex than the left ventricle. Therefore two-dimensional assessment is limited particularly for the measurement of volume. In this study, using three-dimensional transesophageal echocardiography, right-ventricular volume could be determined with good interobserver variability.

43. Shi Y, Denault AY, Couture P, *et al.* Biventricular diastolic filling patterns after coronary artery bypass graft surgery. *J Thorac Cardiovasc Surg* 2006; 131:1080–1086.

44. Gomez CM, Palazzo MG. Pulmonary artery catheterization in anaesthesia and intensive care. *Br J Anaesth* 1998; 81:945–956.
45. Denault AY, Belisle S, Babin D, *et al.* Difficult separation from cardiopulmonary bypass and deltaPCO₂. *Can J Anaesth* 2001; 48:196–199.
46. Demers P, Elkouri S, Martineau R, *et al.* Outcome with high blood lactate levels during cardiopulmonary bypass in adult cardiac operation. *Ann Thorac Surg* 2000; 70:2082–2086.
47. Fischer GW, Lin HM, Krol M, *et al.* Noninvasive cerebral oxygenation may predict outcome in patients undergoing aortic arch surgery. *J Thorac Cardiovasc Surg* 2011; 141:815–821.
- In this study involving 30 patients undergoing aortic surgery, Fisher *et al.* demonstrated a clear relationship between the severity of brain desaturation and severe adverse outcome.
48. Casati A, Fanelli G, Pietropaoli P, *et al.* Monitoring cerebral oxygen saturation in elderly patients undergoing general abdominal surgery: a prospective cohort study. *Eur J Anaesthesiol* 2007; 24:59–65.
49. Casati A, Fanelli G, Pietropaoli P, *et al.* Continuous monitoring of cerebral oxygen saturation in elderly patients undergoing major abdominal surgery minimizes brain exposure to potential hypoxia. *Anesth Analg* 2005; 101:740–747.
50. Murkin JM, Adams SJ, Novick RJ, *et al.* Monitoring brain oxygen saturation during coronary bypass surgery: a randomized, prospective study. *Anesth Analg* 2007; 104:51–58.
51. Heringlake M, Garbers C, Kabler JH, *et al.* Preoperative cerebral oxygen saturation and clinical outcomes in cardiac surgery. *Anesthesiology* 2011; 114:58–69.
- A very important prospective study involving 1178 patients undergoing cardiac surgery in whom brain saturation values were obtained the day before cardiac surgery. The patients were followed for 1 year. The authors demonstrated that nonsurvivors had lower baseline values. In addition, baseline brain saturation below 50% were independently associated with 30 days and 1-year mortality. The study also demonstrate how brain saturation is associated with several variables involved in oxygen transport such as cardiac function and hemoglobin.
52. Maslow A, Stearns G, Bert A, *et al.* Monitoring end-tidal carbon dioxide during weaning from cardiopulmonary bypass in patients without significant lung disease. *Anesth Analg* 2001; 92:306–313.
53. Baraka AS, Aouad MT, Jalbout MI, *et al.* End-tidal CO₂ for prediction of cardiac output following weaning from cardiopulmonary bypass. *J Extra Corpor Technol* 2004; 36:255–257.
54. Denault A, Deschamps A. Abnormal aortic-to-radial arterial pressure gradients resulting in misdiagnosis of hemodynamic instability. *Can J Anesth* 2009; 56:534–536.

55. Markin NW, Montzingo CR, Shillcutt SK, *et al.* Echo rounds: intraoperative transesophageal echocardiography diagnosis of rare source of right ventricular failure after heart transplant. *Anesth Analg* 2012; 115:257–260.
- Excellent discussion on a rare cause of heart failure following heart transplantation secondary to an anastomotic complication at the level of the pulmonary artery. The two-dimensional and color Doppler features are well described. This case report highlight the importance of performing a comprehensive evaluation of cardiac function using TEE after heart transplantation.
56. Lamarche Y, Cheung A, Ignaszewski A, *et al.* Comparative outcomes in cardiogenic shock patients managed with Impella microaxial pump or extracorporeal life support. *J Thorac Cardiovasc Surg* 2011; 142:60–65.
- These authors describe their experience with percutaneous ventricular assist devices such as the Impella system (Abiomed, Inc., Danvers, Massachusetts, USA) in patients with right ventricular failure secondary to left ventricular failure with promising results.
57. Downing SW, Edmunds LH Jr. Release of vasoactive substances during cardiopulmonary bypass. *Ann Thorac Surg* 1992; 54:1236–1243.
58. Martineau A, Arcand G, Couture P, *et al.* Transesophageal echocardiographic diagnosis of carbon dioxide embolism during minimally invasive saphenous vein harvesting and treatment with inhaled epoprostenol. *Anesth Analg* 2003; 96:962–964.
59. Hache M, Denault AY, Belisle S, *et al.* Inhaled prostacyclin (PGI₂) is an effective addition to the treatment of pulmonary hypertension and hypoxia in the operating room and intensive care unit. *Can J Anaesth* 2001; 48:924–929.
60. Hache M, Denault AY, Belisle S, *et al.* Inhaled epoprostenol (prostacyclin) and pulmonary hypertension before cardiac surgery. *J Thorac Cardiovasc Surg* 2003; 125:642–649.
61. Denault AY, Lamarche Y, Couture P, *et al.* Inhaled milrinone: a new alternative in cardiac surgery? *Semin Cardiothorac Vasc Anesth* 2006; 10:346–360.
62. Lamarche Y, Perrault LP, Maltais S, *et al.* Preliminary experience with inhaled milrinone in cardiac surgery. *Eur J Cardiothorac Surg* 2007; 31:1081–1087.
63. Angel Gomez-Sanchez M, Saenz DLCC, Escribano SP, *et al.* Pilot assessment of the response of several pulmonary hemodynamic variables to sublingual sildenafil in candidates for heart transplantation. *Eur J Heart Fail* 2004; 6:615–617.
64. Freitas AF Jr, Bacal F, Oliveira JL Jr, *et al.* Impact of sublingual sildenafil on pulmonary hypertension in patients with heart failure. *Arq Bras Cardiol* 2009; 92:116–126.
65. Gordon C, Collard CD, Pan W. Intraoperative management of pulmonary hypertension and associated right heart failure. *Curr Opin Anesthesiol* 2010; 23:49–56.