Malformations cardiaques congénitales chez l'adulte

Nicolas Rousseau-Saine

R2 – Université de Montréal

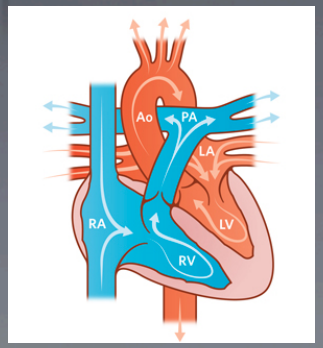

Journée scientifique des résidents

3 mai 2014

Cas clinique

- Femme 41 ans, comptable, un mari, deux enfants
- Chirurgie annoncée: appendicectomie
- ATCD: Migraine
  RX: Advil PRN
  Pas allergie
- Histoire: Douleur FID x 18h, N°
  Fatigue, dyspnée occasionnelle (II/IV), palpitations
- Examen: TA 125/72, Pouls 110, T 38.5, RR 20, Sat 97%
  Coeur et poumons: N
  Abdomen: dlr abdo FID
- Labos: Gb 14, Hb 135, Plt 210
  BhCG: -

ECG:

Fibrillation auriculaire
Déviation axiale droite
ECG anormal

Cas clinique

- Consultation en cardio
  Histoire idem
  Examen: dédoublement B2 fixe et souffle syst II/VI PSG
  ETT: Dilatation légère à modérée de l'oreillette droite
  Communication interauriculaire environ 8 mm
  FEVG: 60%
  Dilatation légère à modérée du VD
  Insuffisance tricuspidienne ¼, PAP 34 /14mmHg

- Transfert vers hôpital spécialisé organisé pour le lendemain

Cas clinique

- Consultation en cardio
  Histoire idem
  Examen: dédoublement B2 fixe et souffle syst II/VI PSG
  ETT: Dilatation légère à modérée de l'oreillette droite
  Communication interauriculaire environ 8 mm
  FEVG: 60%
  Dilatation légère à modérée du VD
  Insuffisance tricuspidienne ¼, PAP 34 /14mmHg

- Transfert vers hôpital spécialisé organisé pour le lendemain

Chirurgien vous appelle:
Abdomen aigu
Lactates en progression

Chirurgie immédiate

Question

- Tous les gestes anesthésiques suivants permettent de diminuer un shunt cardiaque gauche-droit sauf un, lequel?

1. Technique neuraxiale
2. Induction inhalée en spontanée
3. FiO_2 basse
4. Hyperventilation
5. Induction IV

Objectifs

- Connaître la classification des malformations cardiaques congénitales
- Comprendre la physiopathologie de la communication interauriculaire
- Procéder à l'évaluation d'un patient ayant une CIA
- Élaborer un plan de prise en charge anesthésique sécuritaire chez un patient porteur d'une CIA

Pertinence clinique

Knowledge and Attitudes of Anesthesia Providers about Noncardiac Surgery in Adults with Congenital Heart Disease

Bryan G. Maxwell, MD, MPH, Glynn D. Williams, MBChB, and Chandra Ramamoorthy, MBBS

Department of Anesthesia, Stanford University School of Medicine and Lucile Packard Children's Hospital, Stanford, Calif, USA

«Overall knowledge levels [of anesthesiologists] about CHD appear to be low…»

Maxwell et al. Congenit Heart Dis 2014

Épidémiologie

- Incidence 7/1000
- 1-3 millions d'adultes avec MCC (canada et USA)
- 85% des patients avec MCC survivent jusqu'à l'âge adulte
- Âge moyen des patients avec MCC: 40 ans
- Plus de patients adultes avec MCC que pédiatriques

Roune-Rapp et al. Int Anesthesiol Clin, 2012

Classification des MCC

Simple	Moderate complexity	Great complexity

• Minor ASD
• Minor VSD
• Mild PS
• Congenital valve disease
• Aortic or mitral
	• Anomalous pulmonary venous drainage
	• AV canal defects
	• Tetralogy of Fallot
	• Ebstein's anomaly
	• Coarctation of aorta
	• Right ventricular outflow obstruction
	• ASD
	  • Ostium primum
	  • Sinus venosus
	• Persistent PDA
	• PV disease
	  • Stenotic or regurgitant lesions
	• Fistula:
	  • Aorto–LV
	  • Sinus of valsalva
	• VSD associated with the following:
	  • Valve abnormality (mitral, tricuspid)
	  • Aortic insufficiency
	  • RVOTO
	  • Stenotic lesions (AV, RVOT)
	• AV disease
	• Subaortic stenosis
	• Supra-aortic stenosis
		• Single ventricle lesions and Fontan physiology
		  • TA
		  • Mitral atresia
		• Eisenmenger's physiology
		• Cyanotic CHD
		• Existence of conduits—either with valve or without
		• Presence of intracardiac baffles
		• TGV
		  • Jatene procedure
		  • Mustard procedure
		• Truncus arteriosus/hemitruncus

Frederick A. Hensley. A practical approach to cardiac anesthesia. Fifth edition. 2013

Classification MCC

- Corrigées
  - ASD
  - VSD
  - PDA
- Palliées
  - TOF
  - Fontan
  - Transposition des gros vaisseaux
- Non-traitées

Chassot et al. J Cardiothorac Vasc Anesth, 2006

Facteurs indépendants de complication périopératoire

- Arythmies
- Hypertension pulmonaire
- Cyanose
- Réopération
- Dysfonction ventriculaire

Chassot et al. J Cardiothorac Vasc Anesth, 2006

CIA

Épidémiologie

- Représente 7% des MCC
- 30% de la population adulte avec MCC
- 2e plus fréquente MCC chez adulte
- Femme:Homme 2-3:1

Geva et al. Lancet, 2014

Types de CIA

- Secundum (75%)
- Primum (15%)
- Sinus veineux (10%)
- Sinus coronaire (rare)

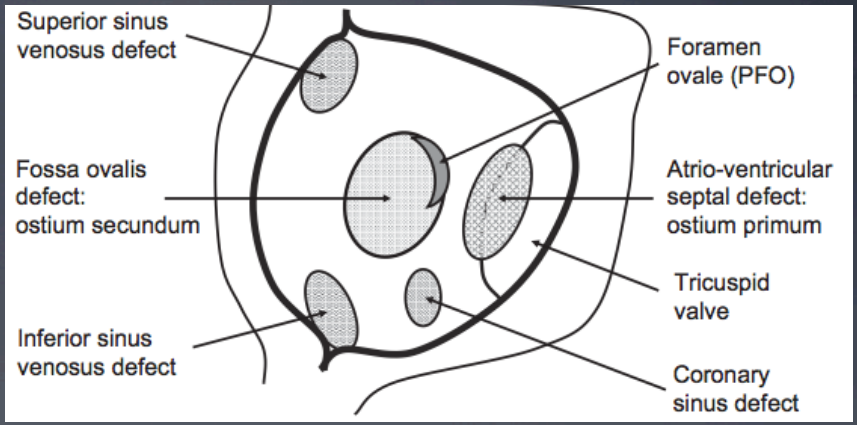

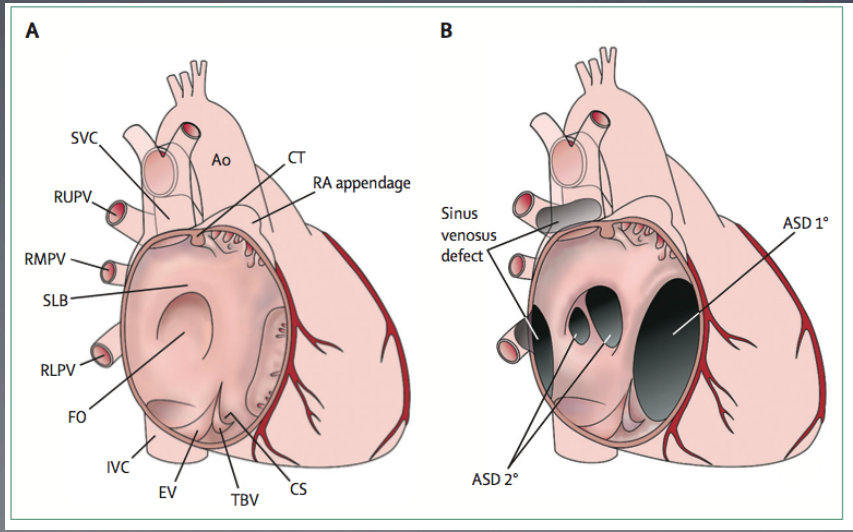

Geva et al. Lancet, 2014
Chassot et al. J Cardiothorac Vasc Anesth, 2006

Physiopathologie CIA

- Shunt principalement gauche ➔droit
- Sévérité du shunt dépend:
  - Largeur de la communication
  - Différentiel de pression des oreillettes
- Shunt gauche ➔droit
  - Fin de systole et début de diastole
  - Contraction auriculaire
  - Expiration
- Shunt droit ➔gauche
  - Début de systole et milieu de diastole
- Évolution graduelle
  - Dilatation AD et VD -> Overflow pulm -> HTAP -> Défaillance D -> Eisenmenger

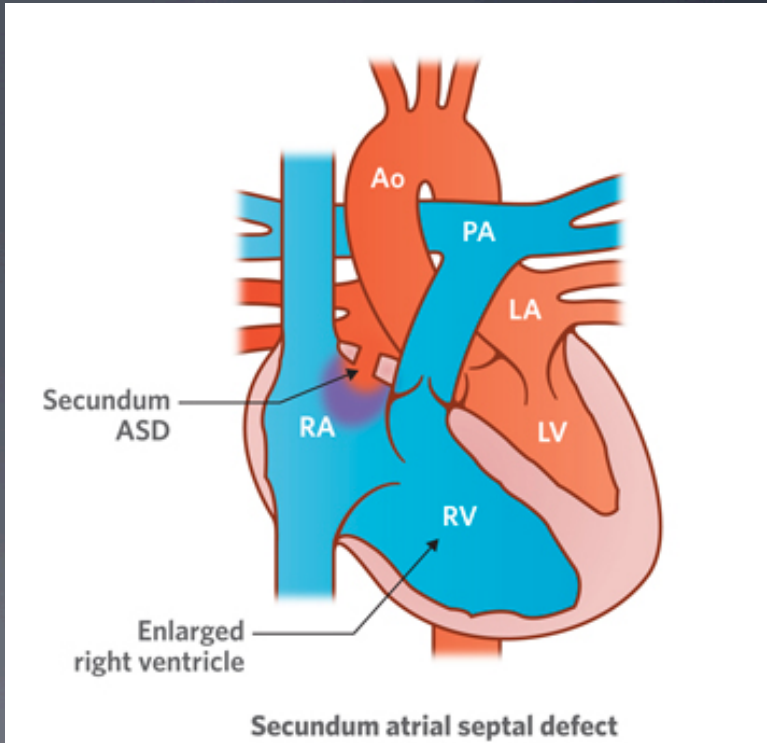

Secundum atrial septal defect

Échographie

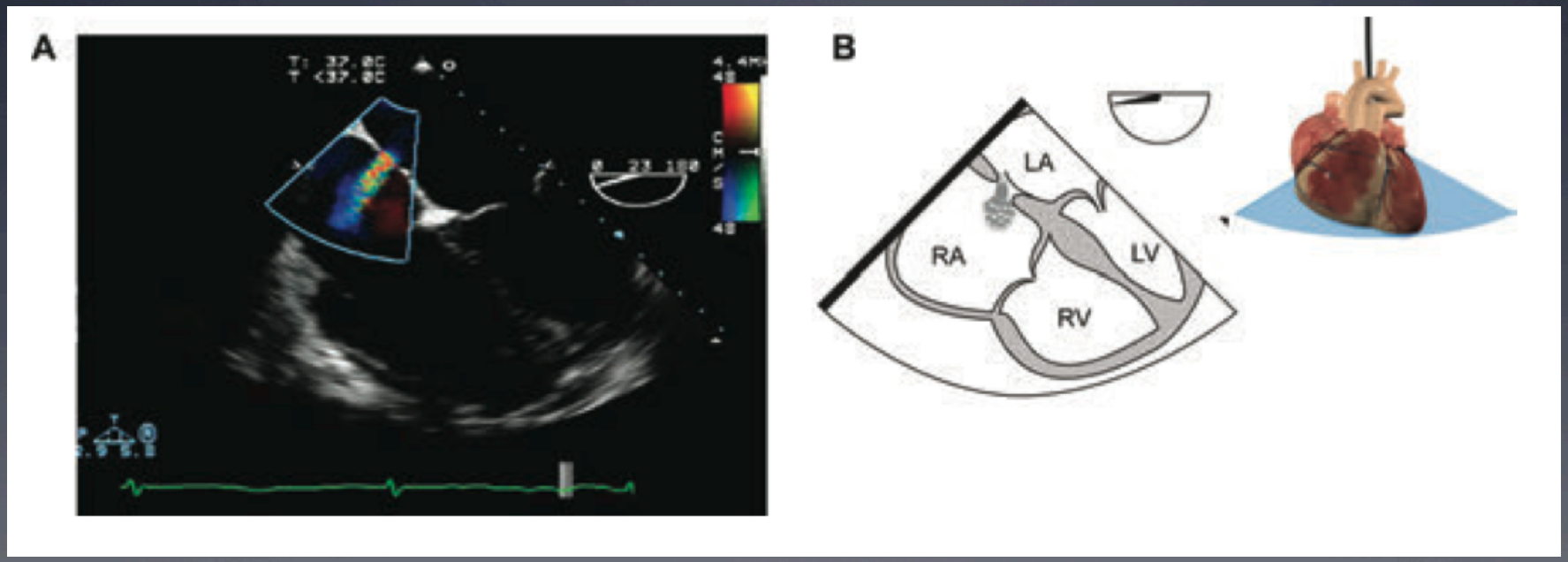

Denault et al. *Transesophageal Echocardiography Multimedia Manual*, 2011

Échographie

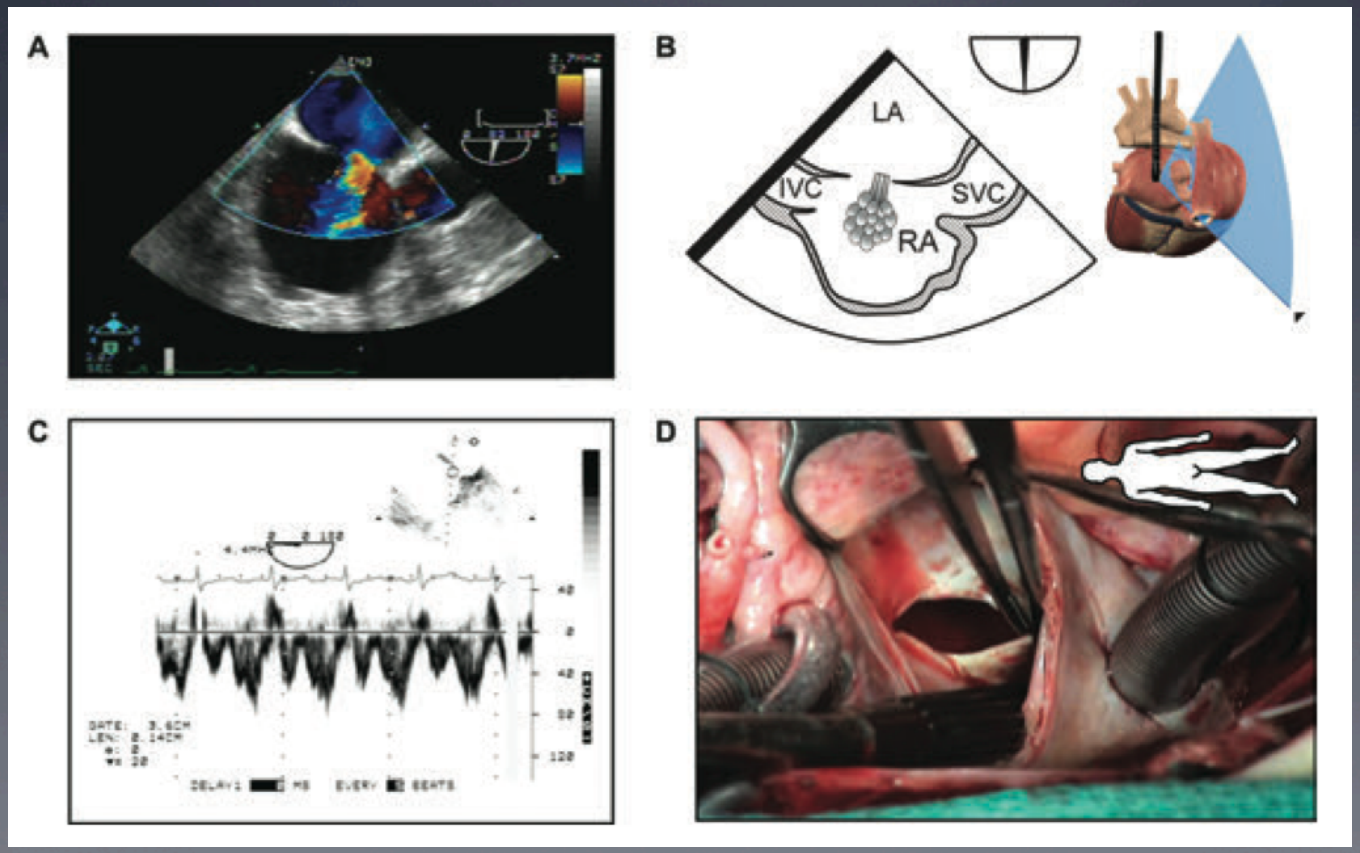

Denault et al. *Transesophageal Echocardiography Multimedia Manual*, 2011

Doppler

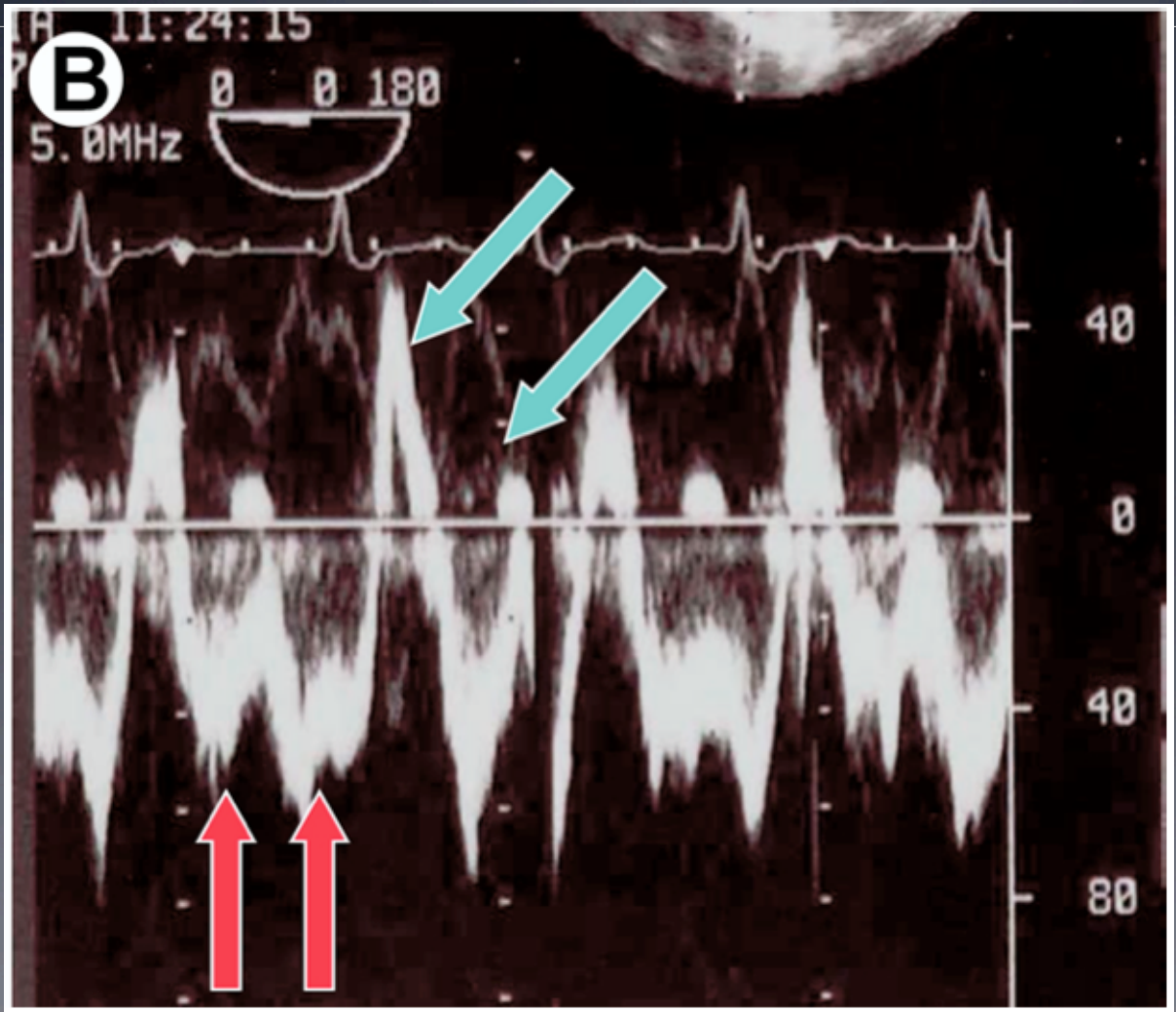

Chassot et al. J Cardiothorac Vasc Anesth, 2006

Concept de Q_{pulm}/Q_{syst}

- Se mesure par cathétérisme ou échographie
- Estimation avec shunt gauche → droit
  - $Qp/Qs = (SaO_2 - SvO_2) / (SpvO_2 - SpaO_2)$
  - $Qp/Qs = (SaO_2 - SvO_2) / (SaO_2 - SpaO_2)$
- Si >1 : shunt G → D
- Si <1 : shunt D → G

Chassot et al. J Cardiothorac Vasc Anesth, 2006

Distribution du flow

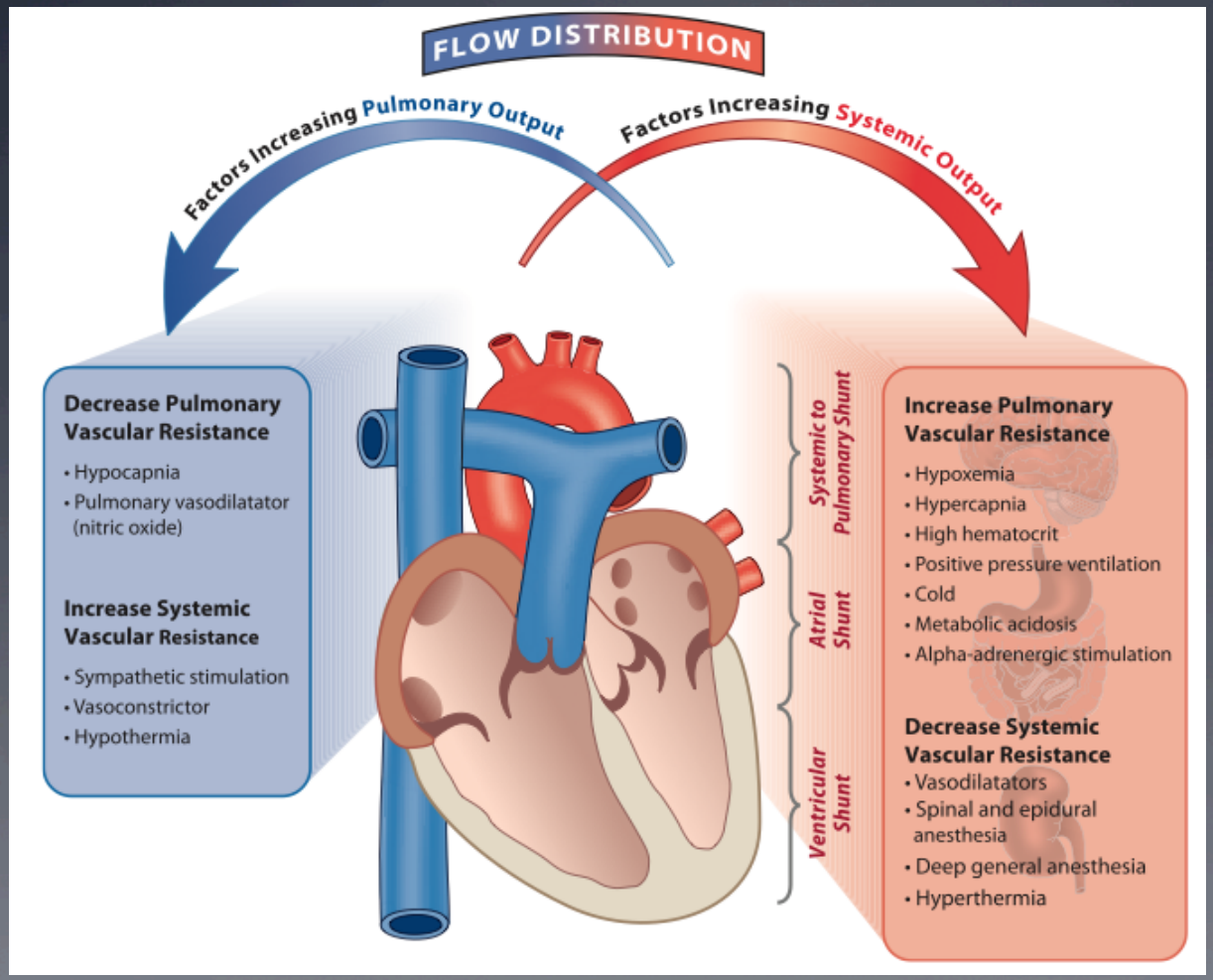

Cannesson et al. Anesthesiology, 2009

Évolution naturelle

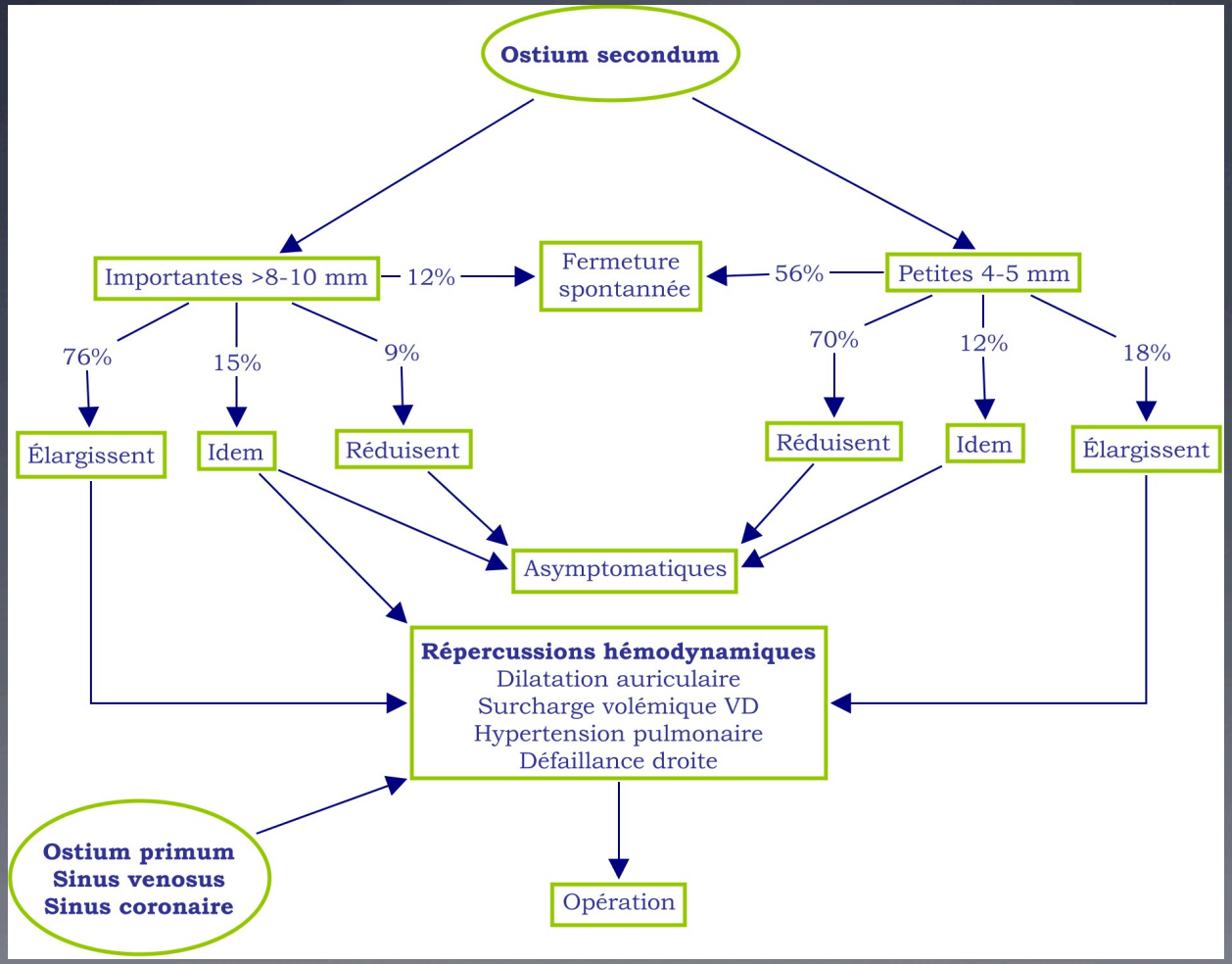

PRÉOPÉRATOIRE

Principes généraux

- Équipe multidisciplinaire
- Les lésions modérées et complexes doivent être prises en charge dans des centres spécialisés (si possible)
- Rechercher les autres comorbidités habituelles
- S'assurer d'avoir tout le matériel nécessaire disponible (ETO, swan, trappes à bulle, défibrillateur)

Présentation clinique

Présentation initiale

- **Dyspnée**
- **Palpitation**
- Cardiomégalie (découverte fortuite)
- Souffle cardiaque
- Fibrillation / flutter auriculaire
- Embolie paradoxale

Examen physique

- Choc apexien élargi
- Souffle systolique pulmonaire
- Dédoublement de B2 fixe
- Souffle diastolique tricuspidien

CIA importante (>10 mm)

- Infections pulmonaires
- Fatigue
- Intolérance à l'effort
- OMI
- Palpitations

Diagnostics associés

- Migraine
- Syndromes :
  - Down
  - Budd-Chiari
  - Jarcho-Levine
  - …

Geva et al. Lancet, 2014

Investigations

- ECG: Axe droit, BBD incomplet, hypertrophie auriculaire droite, arythmie auriculaire
- ETT = examen de choix
  - Recherche les types de CIA et lesions associées
  - Mesure grosseur
  - Évaluation oreillette et ventricule droit
    - Dilatation, pression, valves
  - Évaluation et mesure PaP
  - Direction du shunt (droit➔gauche)
- ETO, IRM et CT-scan: lorsque ETT peu concluante
- Cathétérisme cardiaque: MCAS, Qp/Qs, fermeture CIA

Geva et al. Lancet, 2014

Risque périopératoire

PRACTICE GUIDELINE: FULL TEXT

ACC/AHA 2008 Guidelines for the Management of Adults With Congenital Heart Disease

A Report of the American College of Cardiology/American Heart Association Task Force on Practice Guidelines (Writing Committee to Develop Guidelines on the Management of Adults With Congenital Heart Disease)

Table 7. Congenital Cardiac Lesions and Perioperative Risk for Noncardiac Surgery

High risk
Pulmonary hypertension, primary or secondary
Cyanotic congenital heart disease
New York Heart Association class III or IV
Severe systemic ventricular dysfunction (ejection fraction less than 35%)
Severe left-sided heart obstructive lesions
Moderate risk
Prosthetic valve or conduit
Intracardiac shunt
Moderate left-sided heart obstruction
Moderate systemic ventricular dysfunction

Warnes et al. JACC, 2008

PEROPÉRATOIRE

Principes généraux

- **Critères déterminants**:
  - Importance du shunt et HTAP
- Buts hémodynamiques

  Maintenir shunt gauche ➔droit

  Optimiser la précharge

  Rythme sinusal (viser légère tachycardie)

  Optimiser la contractilité (agents inotropes)

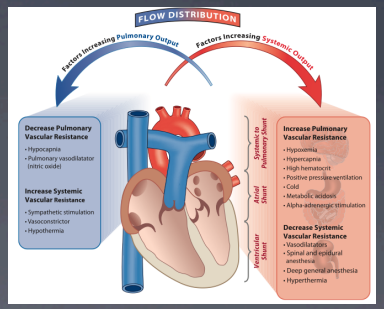

- Sécuriser les solutés avec des **trappes à bulles**
- HTAP

Chassot et al. J Cardiothorac Vasc Anesth, 2006

Monitoring

- Monitoring de base avec ECG 5 dérivations
- **Saturomètre = moniteur de shunt**
- Canule artérielle
- Voie centrale
- Swan: mesure PAP, prélèvement (Qp/Qs)
- ETO

Anesthésie générale

- Induction
  - Propofol > Halogénés : vasodilatation systémique
  - Kétamine : augmentation PAP
  - Opiacés et Benzo: hypercapnie
  - Étomidate : meilleure option (si HTAP)
- Ventilation
  - VAC: Associé pression ventilation élevée
  - VPC: Bon si Vm adéquate avec faible pression
  - PEEP: Renversement du shunt à des valeurs >10
  - VACI : avec faible pression
  - VCRP: Ideal, mais peu disponible
- Laparoscopie: à éviter (surtout si HTAP)
  - Augmente pression de ventilation et $EtCO_2$

Anesthésie neuraxiale

- Vasodilation systémique va diminuer le shunt gauche → droit
- Effet vasodilateur
  - Rachi >>> péridurale
- Bolus péridurale est une meilleure option que la rachi si le temps le permet (surtout si HTAP)
- Éviter les pertes de résistance à l'air

Prophylaxie endocardite

PRACTICE GUIDELINE: FULL TEXT

ACC/AHA 2008 Guidelines for the Management of Adults With Congenital Heart Disease

A Report of the American College of Cardiology/American Heart Association Task Force on Practice Guidelines (Writing Committee to Develop Guidelines on the Management of Adults With Congenital Heart Disease)

Table 6. Cardiac Conditions Associated With the Highest Risk of Adverse Outcome From Endocarditis for Which Prophylaxis With Dental Procedures Is Reasonable

Condition	Congenital Specific Condition*
• Previous infective endocarditis	• Unrepaired cyanotic CHD, including palliative shunts and conduits
• Prosthetic cardiac valve or prosthetic material used for cardiac valve repair	• Completely repaired congenital heart defect with prosthetic material or device, whether placed by surgery or by catheter intervention, during the first 6 months after the procedure†
	• Repaired CHD with residual defects at the site or adjacent to the site of a prosthetic patch or prosthetic device that inhibit endothelialization
	• Cardiac transplant recipients who develop cardiac valvulopathy

*Except for the conditions listed above, antibiotic prophylaxis is no longer recommended for any other form of CHD.

Warnes et al. JACC, 2008

POSTOPÉRATOIRE

Principes généraux

- Extubation bien éveillé
- Soins intensifs selon l'évolution peropératoire
- Soulagement efficace de la douleur
  - Technique régionale si possible
- Arythmies
- État volémique

Conclusion

- Maladies cardiaques congénitales sont de plus en plus présentes chez l'adulte
- Chacune d'elles représente un défi de taille lors de la prise en charge anesthésique
- La CIA produit un shunt bidirectionnel
- Prise en charge anesthésique
  - Bien connaître la physiologie de notre patient
  - Jouer sur les paramètres modifiants cette physiologie

Questions?

Remerciement

- Docteur André Denault
- Anesthésistes de Trois-Rivières
- Docteur Christian Ayoub

Références

- Chassot, Pierre-Guy, and Dominique A Bettex. 2006. "Anesthesia and Adult Congenital Heart Disease.." *Journal of Cardiothoracic and Vascular Anesthesia 20 (3): 414–37.*

- Cannesson, Maxime, Michael G Earing, Vincent Collange, and Judy R Kersten. 2009. "Anesthesia for Noncardiac Surgery in Adults with Congenital Heart Disease.." *Anesthesiology 111 (2): 432–40.*

- Azarbal, Babak, Jonathan Tobis, William Suh, Vicki Chan, Catherine Dao, and Richard Gaster. 2005. "Association of Interatrial Shunts and Migraine Headaches: Impact of Transcatheter Closure.." *Journal of the American College of Cardiology 45 (4):*

- Baum, V C, and J K Perloff. 1993. "Anesthetic Implications of Adults with Congenital Heart Disease.." *Anesthesia & Analgesia 76 (6): 1342–58.*

- Editor, Ariane Marelli MD Section, Luc Beauchesne MD Section Editor, Seema Mital MD, Judith Therrien MD, and Candice K Silversides MD. 2010. "Canadian Cardiovascular Society 2009 Consensus Conference on the Management of Adults with Congenital Heart Disease: Introduction." *Canadian Journal of Cardiology 26 (3). Elsevier: e65–e69.*

- Findlow, D, and E Doyle. 1997. "Congenital Heart Disease in Adults.." *British Journal of Anaesthesia 78 (4): 416–30.*

Références

- Geva, Tal, Jose D Martins, and Rachel M Wald. 2014. "Atrial Septal Defects.." *Lancet.*
- Gottlieb, Erin A, and Dean B Andropoulos. 2013. "Anesthesia for the Patient with Congenital Heart Disease Presenting for Noncardiac Surgery." *Current Opinion in Anaesthesiology 26 (3)*
- Ing, R J, and M D Twite. 2014. "The Year in Review: Anesthesia for Congenital Heart Disease 2013." *Seminars in Cardiothoracic and Vascular Anesthesia 18 (1): 17–23*
- Lovell, A T. 2004. "Anaesthetic Implications of Grown-Up Congenital Heart Disease.." *British Journal of Anaesthesia 93 (1): 129–39.*
- Marelli, Ariane, Luc Beauchesne, Seema Mital, Judith Therrien, and Candice K Silversides. 2010. "Canadian Cardiovascular Society 2009 Consensus Conference on the Management of Adults with Congenital Heart Disease: Introduction.." *The Canadian Journal of Cardiology 26 (3): e65–e69.*
- Maxwell, Bryan G, Glynn D Williams, and Chandra Ramamoorthy. 2014. "Knowledge and Attitudes of Anesthesia Providers About Noncardiac Surgery in Adults with Congenital Heart Disease.." *Congenital Heart Disease 9 (1):.*

Références

- Maxwell, Bryan G, Jim K Wong, Cindy Kin, and Robert L Lobato. 2013. "Perioperative Outcomes of Major Noncardiac Surgery in Adults with Congenital Heart Disease.." *Anesthesiology 119 (4): 762–69.*

- MD, Candice K Silversides, Ariane Marelli MD Section Editor, et al. 2010. "Canadian Cardiovascular Society 2009 Consensus Conference on the Management of Adults with Congenital Heart Disease: Executive Summary." *Canadian Journal of Cardiology 26 (3). Elsevier: 143–50..*

- Monfredi, Oliver, Matthew Luckie, Hoda Mirjafari, Terence Willard, et al. 2013. "Percutaneous Device Closure of Atrial Septal Defect Results in Very Early and Sustained Changes of Right and Left Heart Function.." *International Journal of Cardiology 167 (4)*

- Rouine-Rapp, Kathryn, Isobel A Russell, and Elyse Foster. 2012. "Congenital Heart Disease in the Adult.." *International Anesthesiology Clinics 50 (2): 16–39.*

- Ammash, N M, and C A Warnes. 2001. "Ventricular Septal Defects in Adults.." *Annals of Internal Medicine 135 (9): 812–24.*

- Denault, Couture, Vegas et al. Tranesophageal Echocardiography Multimedia Manual, Second edition, A perioperative transdisciplinary Approach, New York: Informa Health Care; 2011

Références

- Seal, Robert. 2011. "Adult Congenital Heart Disease.." *Paediatric Anaesthesia 21 (5): 615–22*
- Silversides, Candice K, Annie Dore, Nancy Poirier, et al. 2010. "Canadian Cardiovascular Society 2009 Consensus Conference on the Management of Adults with Congenital Heart Disease: Shunt Lesions.." *The Canadian Journal of Cardiology 26 (3): e70–e79.*
- Warnes, Carole A, Roberta G Williams, Thomas M Bashore, et al. 2008. "ACC/AHA 2008 Guidelines for the Management of Adults with Congenital Heart Disease: a Report of the American College of Cardiology/American Heart Association Task Force on Practice Guidelines (Writing Committee to Develop Guidelines on the Management of Adults with Congenital Heart Disease). Developed in Collaboration with the American Society of Echocardiography, Heart Rhythm Society, International Society for Adult Congenital Heart Disease, Society for Cardiovascular Angiography and Interventions, and Society of Thoracic Surgeons.." *Journal of the American College of Cardiology.*
- Webb, Gary, and Michael A Gatzoulis. 2006. "Atrial Septal Defects in the Adult: Recent Progress and Overview.." *Circulation 114 (15): 1645–53.*
- Yuki, Koichi, Alfonso Casta, and Shoichi Uezono. 2011. "Anesthetic Management of Noncardiac Surgery for Patients with Single Ventricle Physiology.." *Journal of Anesthesia 25 (2): 247–56.*

Échographie

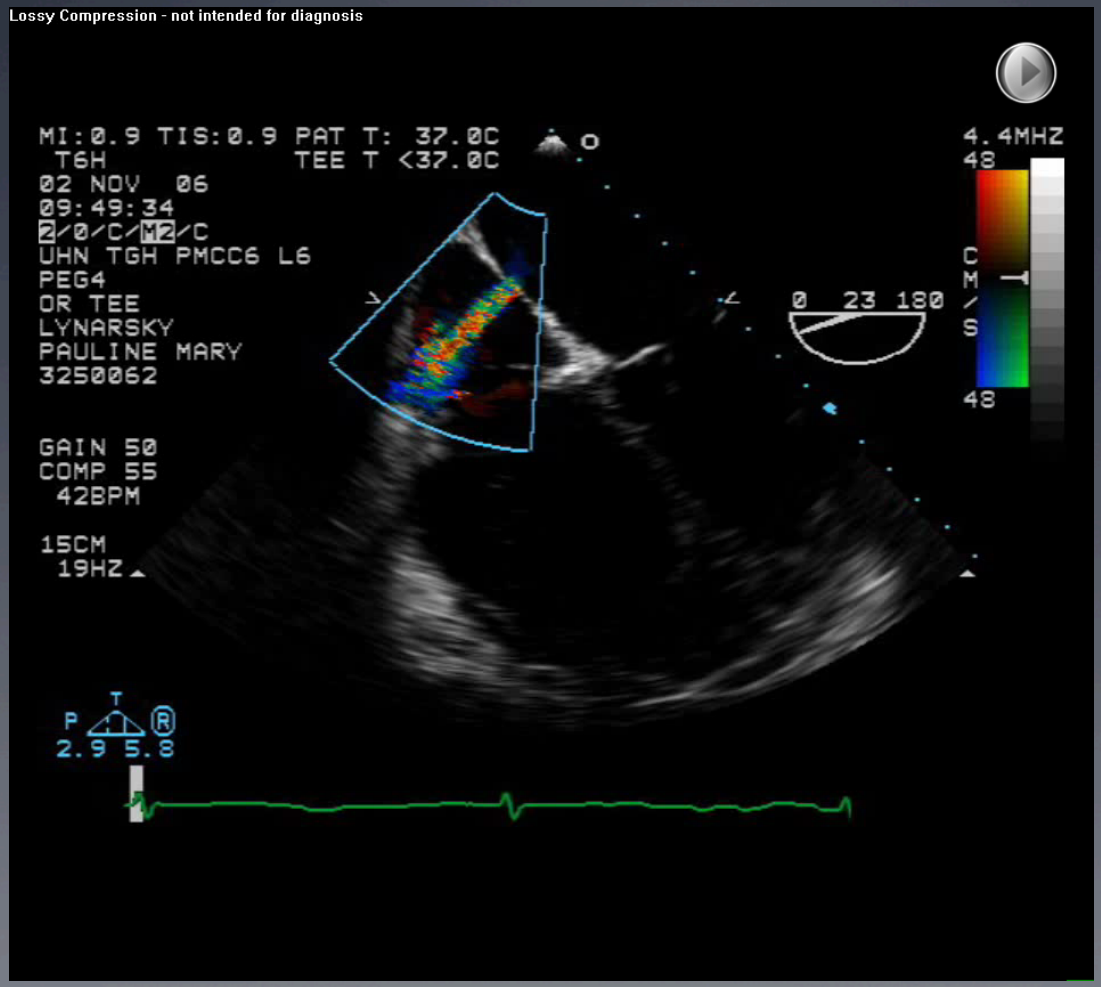

Denault et al. *Transesophageal Echocardiography Multimedia Manual*, 2011

Échographie

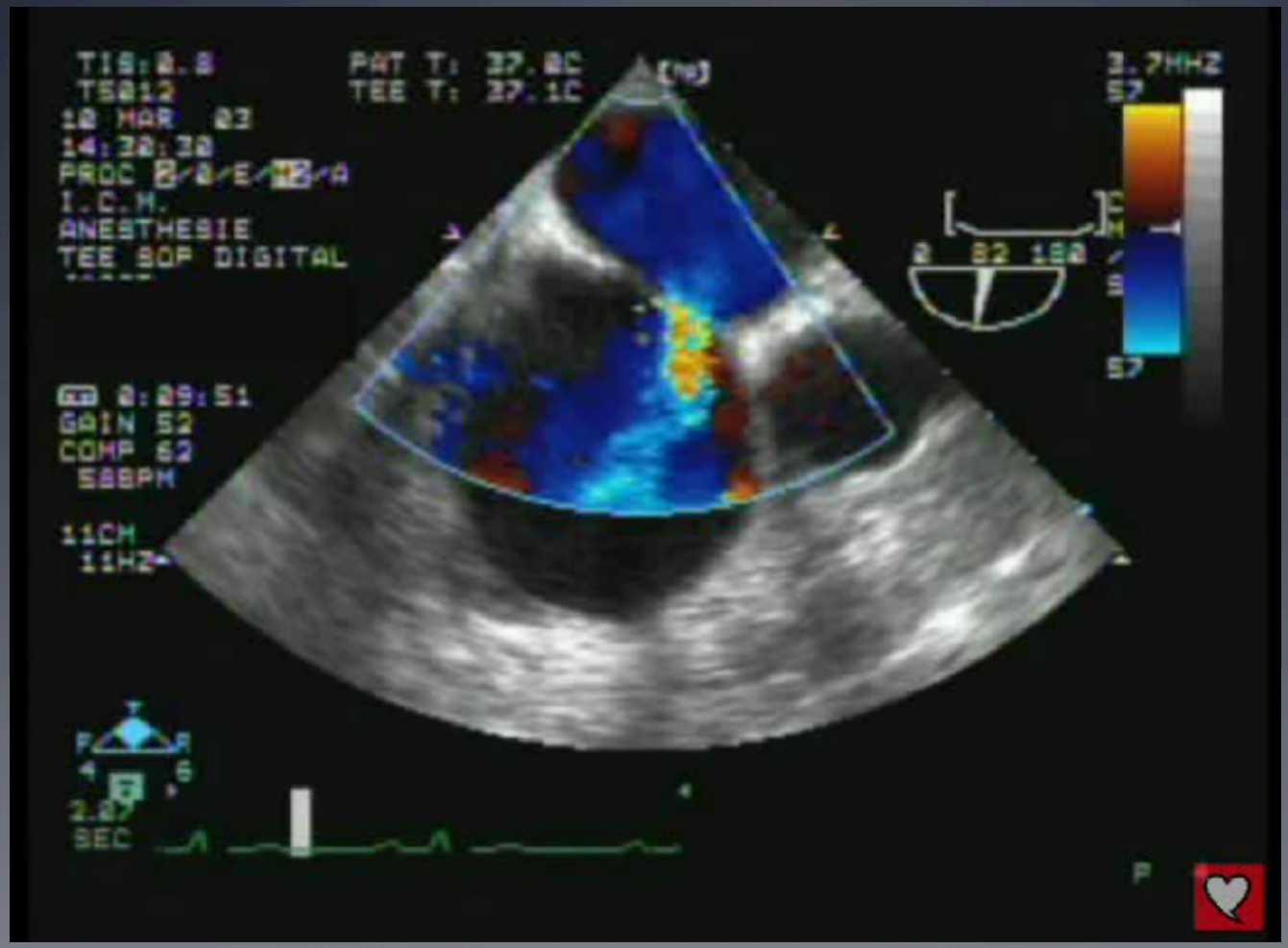

Denault et al. *Transesophageal Echocardiography Multimedia Manual*, 2011

ECG

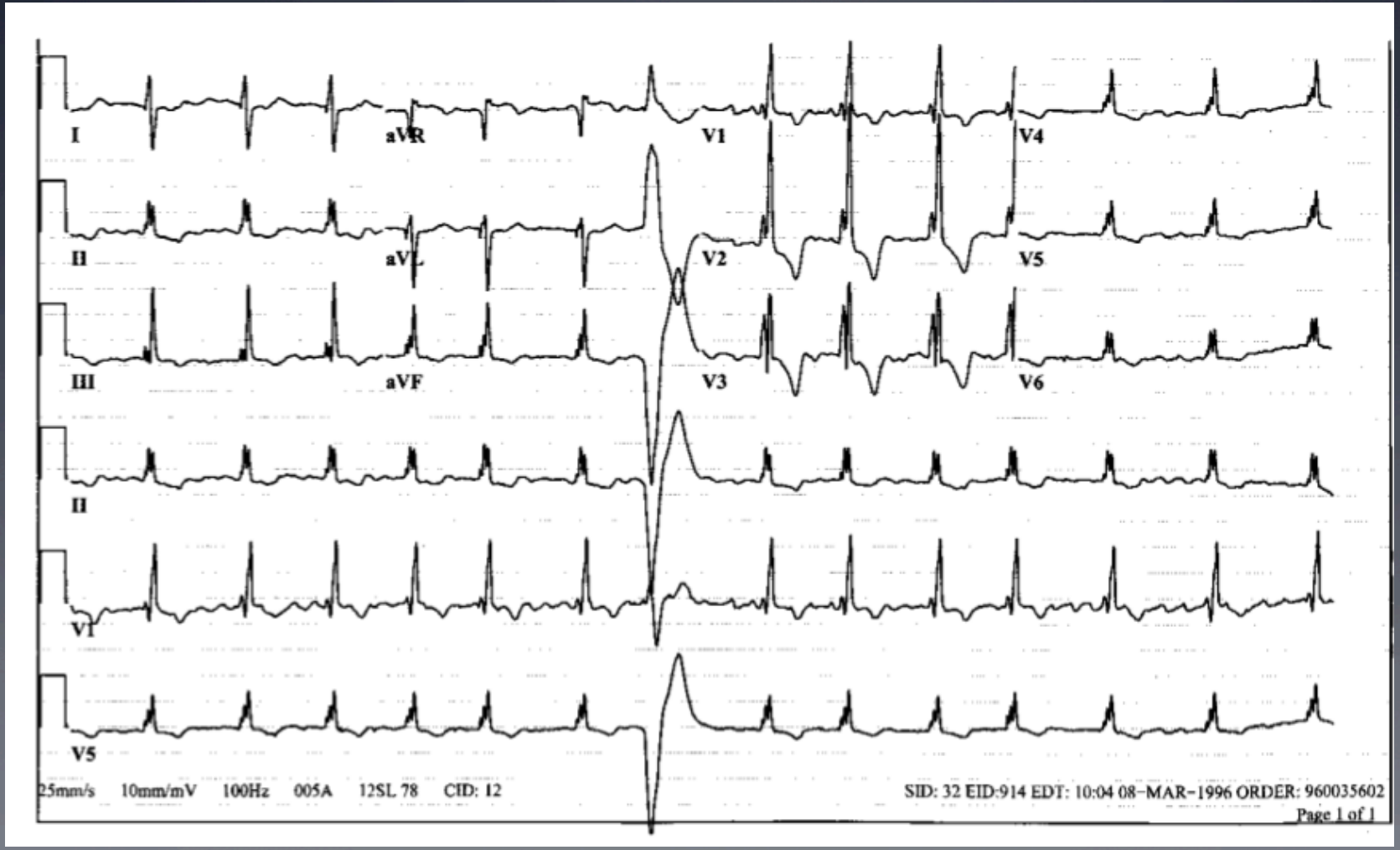

Ammash et al. Ann Intern Med, 2001

Knowledge and Attitudes of Anesthesia Providers about Noncardiac Surgery in Adults with Congenital Heart Disease

Bryan G. Maxwell, MD, MPH, Glynn D. Williams, MBChB, and Chandra Ramamoorthy, MBBS

Department of Anesthesia, Stanford University School of Medicine and Lucile Packard Children's Hospital, Stanford, Calif, USA

Table 1. Respondent Characteristics

	n	%
Male	47	(40%)
Female	71	(60%)
Fellowship		
None	60	(51%)
Pediatric	20	(17%)
Adult cardiac	19	(16%)
Critical care	8	(7%)
Other (OB, regional, pain)	13	(11%)
Does pediatric cases (<2 y)		
>2×/mo	22	(19%)
1–2×/mo	7	(6%)
<1×/mo or never	89	(75%)
Does cardiac cases (involving CPB)		
>2×/mo	19	(16%)
1–2×/mo	7	(6%)
<1×/mo or never	92	(78%)
Does OB cases (analgesia for labor or anesthesia for cesarean delivery)		
>2×/mo	24	(21%)
1–2×/mo	17	(15%)
<1×/mo or never	77	(65%)

OB, obstetric. CPB, cardiopulmonary bypass.

Table 2. Question Concepts in Descending Order of Percent Correct Responses

Concept	% Correct
AV canal and Down syndrome	75%
Shunt and severe pulmonary hypertension	72%
Shunt in Eisenmenger's syndrome	71%
Ebstein's anomaly	68%
Anatomy of a Ross procedure	53%
Position, intrathoracic pressure effects in Fontan circulation	47%
Pulmonic insufficiency after tetralogy repair	47%
Conduit revision after truncus repair	46%
Turner's syndrome and aortic coarctation	40%
Arrhythmias after tetralogy repair	38%
Anatomy of Blalock–Taussig shunt	34%
Arrhythmias in Fontan circulation	33%
Mustard procedure	31%
Anatomy of a Glenn procedure	31%
Anatomy of Fontan circulation	30%
Cyanosis in Eisenmenger's syndrome	28%
Anatomy of aortic coarctation	26%
Anatomy of congenitally corrected transposition (L-TGA)	22%
Williams syndrome	20%
Arterial switch operation	18%

AV, atrioventricular; L-TGA, L-transposition of the great arteries.

Maxwell et al. Congenit Heart Dis 2014

Knowledge and Attitudes of Anesthesia Providers about Noncardiac Surgery in Adults with Congenital Heart Disease

Bryan G. Maxwell, MD, MPH, Glynn D. Williams, MBChB, and Chandra Ramamoorthy, MBBS

Department of Anesthesia, Stanford University School of Medicine and Lucile Packard Children's Hospital, Stanford, Calif, USA

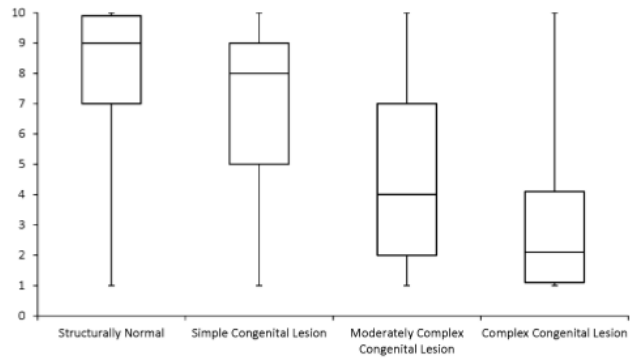

Figure 1. Self-identified comfort using transesophageal echocardiography. Box-and-whisker plot showing the median (central line within box), interquartile range (upper and lower borders of box), and range (error bars) for 10-point Likert scale responses indicating degree of agreement (1 = strongly disagree, 10 = strongly agree) with the statement, "In an adult patient with a _____, I would feel comfortable using transesophageal echocardiography to assess volume status and ventricular function." *X*-axis labels correspond to the patient subset identified in the blank of the statement.

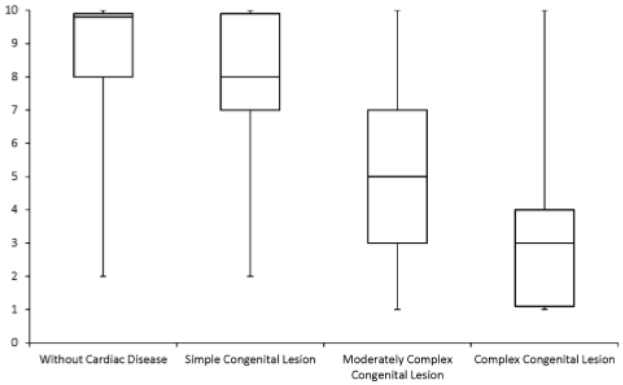

Figure 2. Self-identified understanding of cardiovascular physiology in pregnancy. Box-and-whisker plot showing the median (central line within box), interquartile range (upper and lower borders of box), and range (error bars) for 10-point Likert scale responses indicating degree of agreement (1 = strongly disagree, 10 = strongly agree) with the statement, "I feel confident about my understanding of the cardiovascular physiology of pregnancy and delivery in a patient _____." *X*-axis labels correspond to the patient subset identified in the blank of the statement.

Maxwell et al. Congenit Heart Dis 2014

Indications chirurgicales

PRACTICE GUIDELINE: FULL TEXT

ACC/AHA 2008 Guidelines for the Management of Adults With Congenital Heart Disease

A Report of the American College of Cardiology/American Heart Association Task Force on Practice Guidelines (Writing Committee to Develop Guidelines on the Management of Adults With Congenital Heart Disease)

CLASS I

1. Closure of an ASD either percutaneously or surgically is indicated for right atrial and RV enlargement with or without symptoms. (*Level of Evidence: B*)
2. A sinus venosus, coronary sinus, or primum ASD should be repaired surgically rather than by percutaneous closure. (*Level of Evidence: B*)
3. Surgeons with training and expertise in CHD should perform operations for various ASD closures. (*Level of Evidence: C*)

CLASS IIa

1. Surgical closure of secundum ASD is reasonable when concomitant surgical repair/replacement of a tricuspid valve is considered or when the anatomy of the defect precludes the use of a percutaneous device. (*Level of Evidence: C*)
2. Closure of an ASD, either percutaneously or surgically, is reasonable in the presence of:
   a. Paradoxical embolism. (*Level of Evidence: C*)
   b. Documented orthodeoxia-platypnea. (*Level of Evidence: B*)

CLASS IIb

1. Closure of an ASD, either percutaneously or surgically, may be considered in the presence of net left-to-right shunting, pulmonary artery pressure less than two thirds systemic levels, PVR less than two thirds systemic vascular resistance, or when responsive to either pulmonary vasodilator therapy or test occlusion of the defect (patients should be treated in conjunction with providers who have expertise in the management of pulmonary hypertensive syndromes). (*Level of Evidence: C*)
2. Concomitant Maze procedure may be considered for intermittent or chronic atrial tachyarrhythmias in adults with ASDs. (*Level of Evidence: C*)

CLASS III

1. Patients with severe irreversible PAH and no evidence of a left-to-right shunt should not undergo ASD closure. (*Level of Evidence: B*)

Warnes et al. JACC, 2008

Lésions associées

PRACTICE GUIDELINE: FULL TEXT

ACC/AHA 2008 Guidelines for the Management of Adults With Congenital Heart Disease

A Report of the American College of Cardiology/American Heart Association Task Force on Practice Guidelines (Writing Committee to Develop Guidelines on the Management of Adults With Congenital Heart Disease)

Table 8. Atrial Septal Defects and Associated Lesions

Type of Atrial Septal Defect	Associated Lesions
Secundum	• Pulmonic stenosis • Mitral valve prolapse • Partial anomalous pulmonary venous connection
Primum	• Cleft mitral valve • Discrete subaortic stenosis
Sinus venosus	• Partial anomalous pulmonary venous return
Coronary sinus	• Partial anomalous pulmonary venous return • Persistent left superior vena cava

Warnes et al. JACC, 2008

Management FA

PRACTICE GUIDELINE: FULL TEXT

ACC/AHA 2008 Guidelines for the Management of Adults With Congenital Heart Disease

A Report of the American College of Cardiology/American Heart Association Task Force on Practice Guidelines (Writing Committee to Develop Guidelines on the Management of Adults With Congenital Heart Disease)

CLASS I

1. Cardioversion after appropriate anticoagulation is recommended to attempt restoration of the sinus rhythm if atrial fibrillation occurs. (*Level of Evidence: A*)
2. Rate control and anticoagulation are recommended if sinus rhythm cannot be maintained by medical or interventional means. (*Level of Evidence: A*)

1.9.3. Atrial Fibrillation

Although far less common than IART in ACHD patients, atrial fibrillation is no less difficult to treat. It occurs most often in patients with congenital AS, mitral valve disease, or palliated single ventricles (161). Management principles are similar to atrial fibrillation encountered in other forms of heart disease, beginning with medical therapy for anticoagulation and ventricular rate control as needed, followed by electrical cardioversion. Class III antiarrhythmic agents may offer protection against recurrence of atrial fibrillation for some patients, but as in the case of IART, drug therapy has been only marginally successful for this group. Also similar to IART, pacemaker implantation may reduce atrial fibrillation episodes in patients with concomitant sinus node dysfunction. Successful elimination of atrial fibrillation has also been reported after combined right and left atrial Maze operations, which may be reasonable to consider if a patient requires cardiac surgery to address hemodynamic issues. Catheter ablation has not yet been extended in any systematic way to atrial fibrillation in the ACHD patient population.

Warnes et al. JACC, 2008

Fermeture percutanée

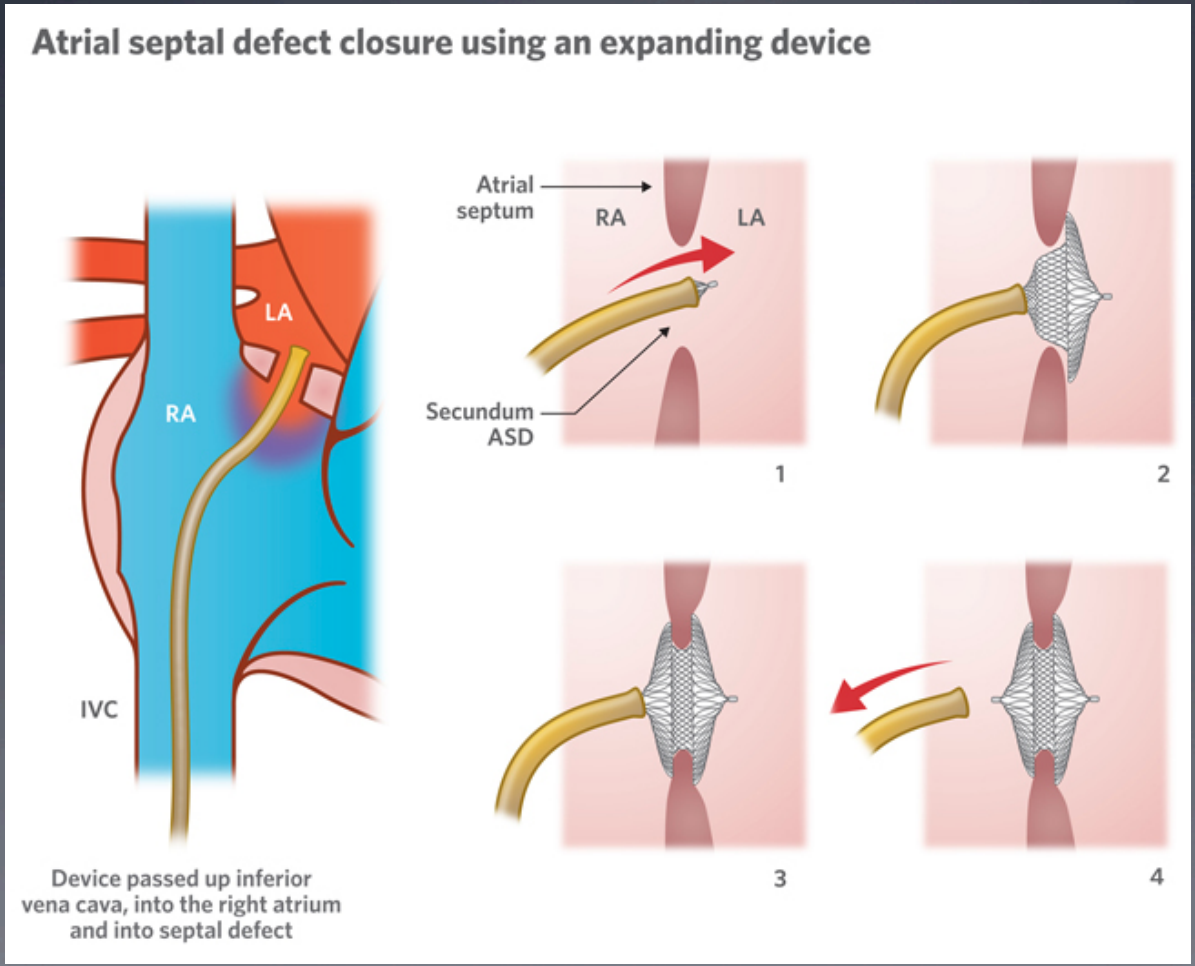

http://www.rch.org.au

Shunt droit → gauche

- Lors des baisses de pressions intra thoraciques subites: Le retour veineux au coeur droit est augmenté et le retour veineux au coeur gauche est réduit.
  - Respiration spontannée
  - Relaxation d'un valsalva
  - Manoeuvre de Mueller
- Lorsque la post-charge du Vd est augmentée
- Ventilation VACI
- Peep >10-15 cm H_2O (ou relachement d'un peep >18-19 cm H_2O

Trappes à bulles



Direction du shunt

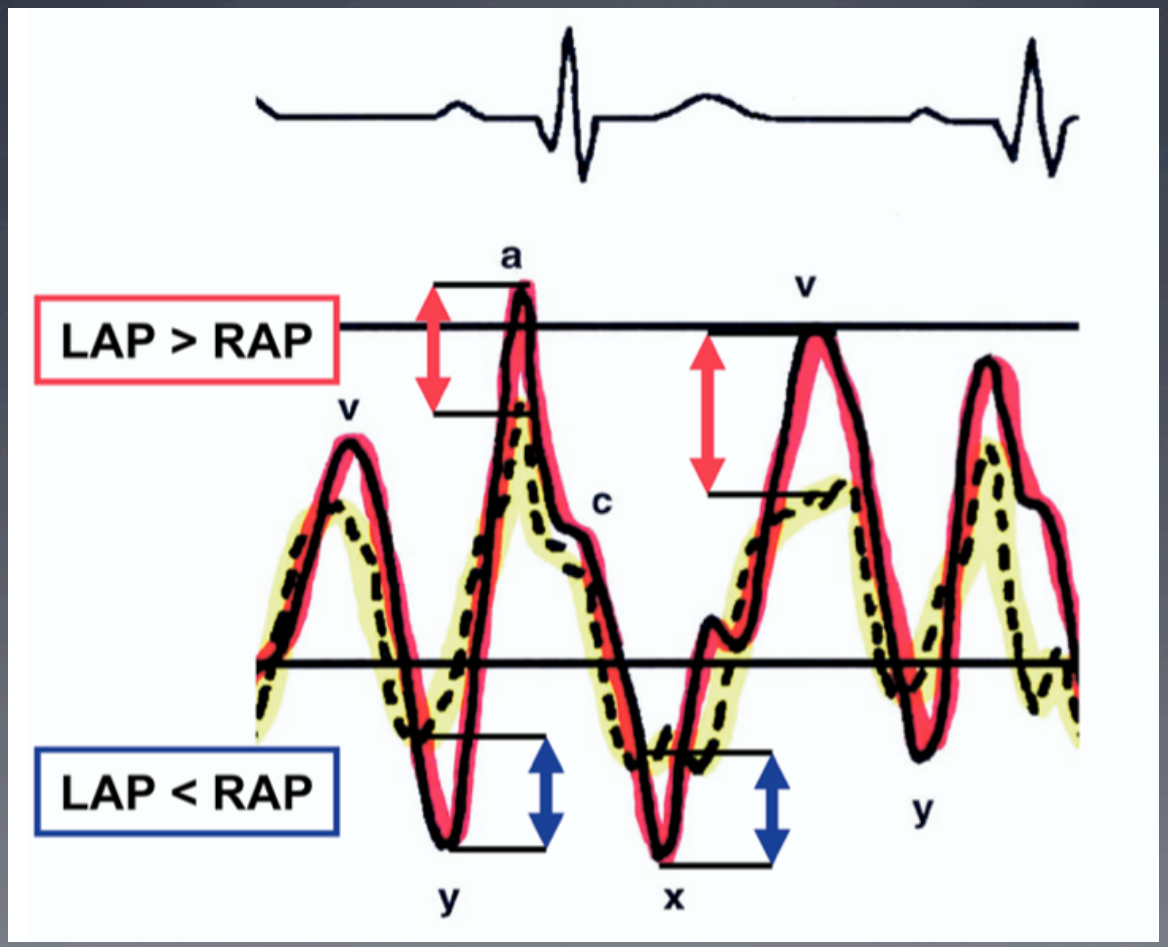

Chassot et al. J Cardiothorac Vasc Anesth, 2006

En résumé

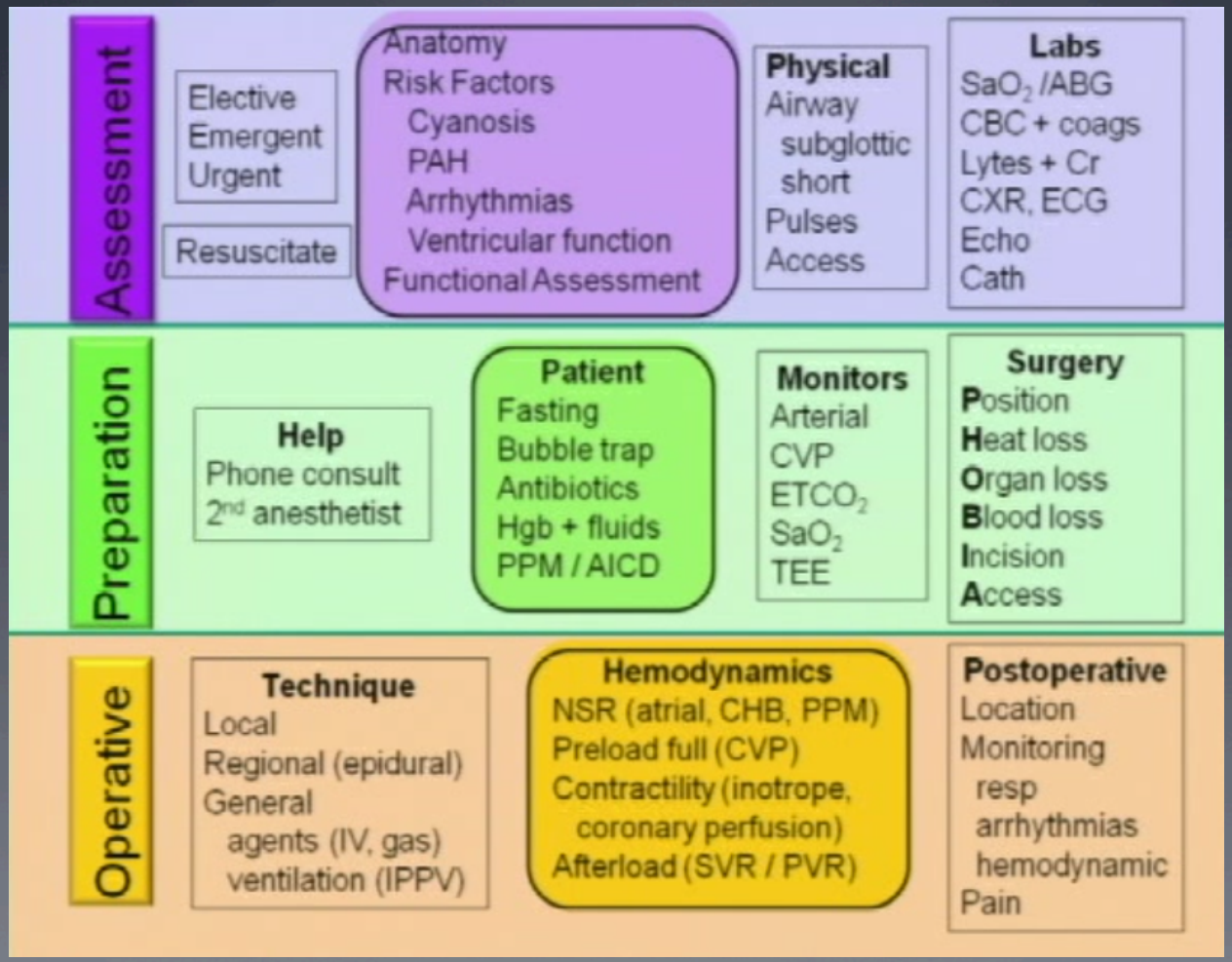

Annette Vegas, Making A Mark, 2013